Medicina Clínica Práctica 9 (2026) 100531

Contents lists available at ScienceDirect

Medicina Clínica Práctica

journal homepage: www.elsevier.es/medicinaclinicapractica

Images in medicine

Pleomorphic adenoma of the parapharyngeal space: A common tumor at an uncommon location

Adenoma pleomorfo del espacio parafaríngeo: Un tumor frecuente en una localización inusual

Alexandra Cortés-Arciniegas [a,*], Saúl Astray-Gómez [a], Germán Martín-Viguer [a], Diego Collado-Martín [a], José María Perolada-Valmaña [a,b], Miguel Armengot-Carceller [a,b]

[a] *Department of Otorhinolaryngology, Hospital Universitari i Politècnic La Fe, Valencia, Spain*
[b] *Department of Surgery, Faculty of Medicine and Dentistry, University of Valencia, Valencia, Spain*

A 47-year-old woman presented with persistent odynophagia. Physical examination revealed a firm bulge of the right anterior peritonsillar pillar, and nasopharyngolaryngoscopy showed a right lateral pharyngeal wall protrusion. CT and MRI identified a 5-cm solid, extramuscular mass in the right pre-styloid parapharyngeal space, exerting mass effect on the medial pterygoid muscle and displacing the tongue base, in close contact with the deep lobe of the parotid gland, without vascular invasion (Fig. 1). Complete resection was performed via a transcervical approach, with sectioning of the posterior belly of the digastric muscle and resection of the styloid process, without complications. Histopathology confirmed a pleomorphic adenoma. Recovery was uneventful, with no recurrence at 18 months.

Parapharyngeal space tumors are rare, representing ~ 0.5% of head and neck neoplasms. Most are benign, with pleomorphic adenoma being the most frequent. Their deep location often renders them asymptomatic, occasionally manifesting as oropharyngeal bulging, cervical mass, odynophagia, or cranial nerve deficits. Diagnosis relies on imaging and histopathology. Complete excision remains the treatment of choice; however, it is surgically challenging due to the tumor's deep location and proximity to vital neurovascular structures. The transcervical approach enables safe and effective resection of selected tumors, with low morbidity and favorable functional outcomes.

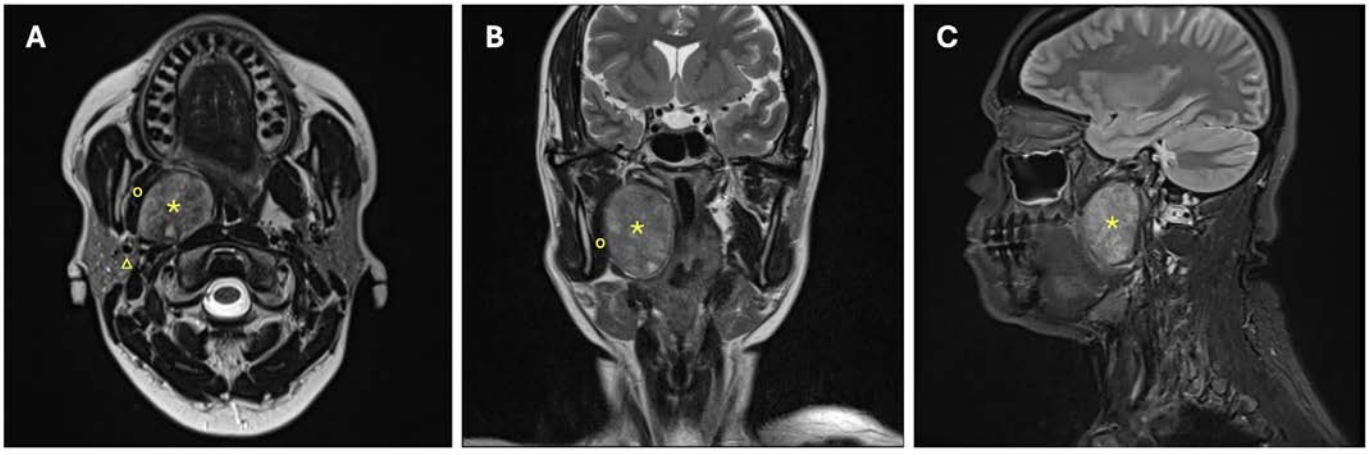

Figure 1. Maxillofacial magnetic resonance imaging (MRI), T2-weighted sequence, axial (A), coronal (B), and sagittal (C) sections, revealing a 5-cm solid, extramuscular tumor (*) located in the right prestyloid parapharyngeal space, exerting mass effect on the medial pterygoid muscle (°) and displacing the oropharynx and base of the tongue. The tumor was in close contact with the deep lobe of the parotid gland (△) and did not present vascular invasion.

* Corresponding author at: Department of Otorhinolaryngology, Hospital Universitari i Politècnic La Fe, Fernando Abril Martorell Avenue 106, 46026 Valencia, Spain.
E-mail address: cortes_alearc@gva.es (A. Cortés-Arciniegas).

http://dx.doi.org/10.1016/j.mcpsp.2025.100531
Received 8 November 2025; Accepted 1 December 2025
Available online 24 December 2025
2603-9249/© 2025 The Author(s). Published by Elsevier España, S.L.U. This is an open access article under the CC BY-NC-ND license (http://creativecommons.org/licenses/by-nc-nd/4.0/).

Ethical considerations

Procedures followed here were in accordance with the ethical standards of the responsible committee on human experimentation and with the Helsinki Declaration of 1975, as revised in 1983. We have not used patients' names, initials, or hospital numbers.

Authorship

All authors had access to the data and played a role in writing this manuscript.

Funding

No specific funding was received from any bodies in the public, commercial or not-for-profit sectors to carry out the work described in this article.

Conflicts of interest

The authors have declared no conflicts of interest.