scientific reports

Check for updates

OPEN

Predictive factors for the success of the Paul glaucoma implant: a one-year multicenter prospective study

Elena Millá[1], Javier Moreno-Montañés[2]✉, Susana Duch[3], Aitor Lanzagorta[4], Jesús Téllez[5], José Vicente Piá[4], Elena Arrondo[6], Jorge Vila[7], Alfonso Antón[8], Javier Bóveda[9], Jordi Loscos[10] & The Spain' Paul Glaucoma Implant Group (SPGG)[21]

The Paul Glaucoma Implant (PGI) is becoming increasingly used in many countries. The primary aim of this study was to identify the most important pre-, intra- and post-operative factors associated with successful intraocular pressure (IOP) control at one year. A total of two hundred and fifty -one eyes from 239 glaucoma patients undergoing PGI surgery were included in this prospective, multicentre, longitudinal study. Clinical data were collected on a REDCap platform using a standardised surgical protocol. Variables were recorded pre-, intra- and postoperatively. Univariable and multivariable logistic regression were used to identify predictors of complete success at one year. These results are expressed as Odds Ratios (OR) and their 95% confidence intervals (95% CI). Kaplan–Meier survival analysis was also performed. Mean IOP was significantly reduced from 25.3 ± 8.8 mmHg preoperatively to 13.1 ± 3.9 mmHg at one year ($p < 0.001$). The medication burden decreased from 3.03 ± 1.12 to 0.78 ± 0.96 ($p < 0.001$). Most complications were minor and self-limiting. Factors associated with complete success in univariable or multivariable analysis were: use of intraoperative antimetabolites (mitomycin or 5-fluorouracil) [OR 2.59; 95% CI 1.18–5.67], combined phacoemulsification-PGI surgery [OR 4.38; 95% CI 1.10–17.36] and removal of the ripcord after 4–5 months [OR 2.36; 95% CI 1.07–5.18]. High myopia was only associated in the univariable analysis (OR 0.50; CI 0.30–0.85; $p = 0.010$). Previous glaucoma surgery, hypertensive phase, surgeon experience and diagnosis of non-open angle glaucoma were not significantly associated with complete success. This study concluded that the effectiveness of the PGI can be enhanced by implementing certain strategies that have not shown similar benefits in Ahmed or Baerveldt glaucoma devices.

Keywords Paul glaucoma implant, Glaucoma drainage device, Intraocular pressure, Prognostic factors

Glaucoma drainage devices (GDD) are widely used in the treatment of glaucoma that does not respond to medications or filtrating surgery. GDDs have shown a similar efficacy in IOP control as standard trabeculectomy[1,2]. These implants facilitate the egress of aqueous humor to a subconjunctival reservoir, bypassing the physiological outflow pathways. Among GDDs, two main categories exist: valved (e.g., Ahmed Glaucoma Valve) and non-valved (e.g., Baerveldt Glaucoma Device, Molteno implant). While valved devices offer early intraocular pressure (IOP) control with reduced hypotony risk, non-valved devices often achieve better long-term pressure reduction at the cost of a higher risk of early postoperative hypotony[3]. The Paul Glaucoma Implant (PGI) (Advanced Ophthalmic Innovations, Singapore, Republic of Singapore) is a free-flow GDD with a plate similar in shape and size (297 mm^2), to the Baerveldt Glaucoma Device (BGD)(Johnson & Johnson Vision, Jacksonville, FL, USA), albeit with a significantly narrower tube with an internal diameter of 127 microns, in contrast to BGD tube of 300 microns. The PGI is functional immediately, as the tube is not ligated as with a BGD, but rather uses an intraluminal ripcord to provide an IOP gradient sufficient to avoid hypotony[4–6]. Owing to its specialized

[1]Hospital Clinic de Barcelona, Universitat de Barcelona, Barcelona, Spain. [2]Clínica Universidad de Navarra, Pamplona, Spain. [3]Verte-ICO, Innova Ocular, Barcelona, Spain. [4]Fundació Oftalmologia Mèdica de la Comunitat Valenciana, Valencia, Spain. [5]Hospital de S. Pau, Barcelona, Spain. [6]Instituto Microcirurgia Ocular (IMO) Grupo Miranza, Universidad Autónoma de Barcelona, Barcelona, Spain. [7]Hospital Universitario La Fe, Universidad de Valencia, Valencia, Spain. [8]Institut Catalá de la Retina, Universitat Internacional de Catalunya, Barcelona, Spain. [9]Complejo Hospitalario de Pontevedra, Pontevedra, Spain. [10]Hospital Universitario Hermanos Trias y Pujol, Universitat Autònoma de Barcelona, Badalona, Spain. [21]List of authors and their affiliations appear at the end of the paper. ✉email: javmormon@gmail.com

design—featuring a thinner tube and a larger effective filtration area while maintaining filtration efficiency—the PGI has shown an enhanced safety profile.

The PGI is progressively positioning itself within the current glaucoma surgical algorithm as a valuable option for moderate to advanced glaucoma cases, particularly when filtering surgery is contraindicated or has failed, and when a long-term solution with lower endothelial risk is desirable. Its surgical implantation technique closely resembles that of other widely used devices, such as the Baerveldt or Ahmed implants, making it accessible to experienced surgeons. Owing to its demonstrated efficacy and favorable safety profile, it is increasingly being considered as a primary GDD option when a GDD is required. Furthermore, in light of recent publications, the PGI may be expanding its indications beyond those traditionally reserved for GDD, potentially broadening its role in surgical glaucoma management[7]. However, given that the structural design of the PGI differs substantially from the other non-valved, large-bore GDDs, it is plausible that the mechanisms underlying its success may also differ. Therefore, predictive factors associated with the efficacy of traditional GDDs, such as the Baerveldt or Ahmed implants, may not be fully applicable or extrapolable to the PGI. This underscores the need for specific, dedicated studies to determine the most relevant clinical variables influencing PGI outcomes, allowing us to optimize its use in real-world settings. In this study we analyzed the effect on IOP through the results of The Spain Paul Glaucoma Implant Group at 1 year follow-up. The main goal of our analysis was to identify the critical preoperative, intraoperative and postoperative factors related to the success of PGI as a mean of IOP control.

Results

Two hundred and fifty-one eyes (from 239 patients) were included in this study with a mean age of 66.8 ± 14.6 years. Demographic data of patients is shown in Table 1. The majority of eyes had primary or secondary open angle glaucoma, and 172 eyes (68.5%) had previously undergone glaucoma surgery.

The IOP decreased from 25.3 ± 8.8 mmHg preoperatively to 13.1 ± 3.9 mmHg at one year. At all postoperative intervals, IOP was significantly lower than preoperative IOP ($p < 0.001$) (Fig. 1). In addition, the number of topical medications decreased from 3.03 ± 1.12 preoperatively to 0.78 ± 0.96 at 1 year postoperatively ($p < 0.001$) as shown in Table 2. Therefore, the IOP decreased by 48.2% and the number of medications decreased by 74.2% at 1 year. The complete success rate was 52.6% and the qualified success rate was 92.8% at 1 year. Kaplan–Meier survival curves are shown in Fig. 2.

Table 3 shows early and late complications. The incidence of hypotony (IOP < 6 mmHg) was 8.4% at the first postoperative visit, decreasing progressively to 4.9% at week 1, 1.6% at 1 month, 1.3% at 3 months, and 1.1% at 6 months. No cases of hypotony were observed at the 12-month follow-up. Only 6 eyes presented with shallow anterior chamber the day after surgery, and in one eye right after the ripcord was removed. An early hypertensive

Variable	Value
N	251 eyes (239 patients)
Age, years (mean + sd)	66.8 ± 14.6
Sex, Men / Women (n)	125 / 114
Eye, right / left (n)	125 / 126
Glaucoma Types: n (%)	
Primary Open Angle Glaucoma	108 (43.0)
Primary closed angle glaucoma	24 (9.6)
Pseudoexfoliative glaucoma	27 (10.8)
Pigmentary glaucoma	4 (1.6)
Juvenile glaucoma	13 (5.2)
Imflammatory glaucoma	11 (4.4)
Steroid induced glaucoma	4 (1.6)
Neovascular glaucoma	21 (8.4)
Misdirection glaucoma	2 (0.8)
Traumatic glaucoma	3 (1.2)
Silicone oil induced glaucoma	3 (1.2)
Miscellaneous: Aniridia, Axenfeld-Rieger, Penetrating keratoplasty, etc	31 (12.3)
Previous Surgery, Yes/No (n)	224/27
Types of Previous Surgery: n (%)	
Subconjunctival MIGS	15 (6.0)
Trabecular MIGS	6 (2.4)
Deep sclerectomy /Trabeculectomy	132 (52.6)
Baerveldt Implant	3 (1.2)
Ahmed implant	16 (6.4)
Cataract Surgery	135 (53.8)
Others: Pterygium, strabismus, etc	81 (32.3)

Table 1. Demographic data.

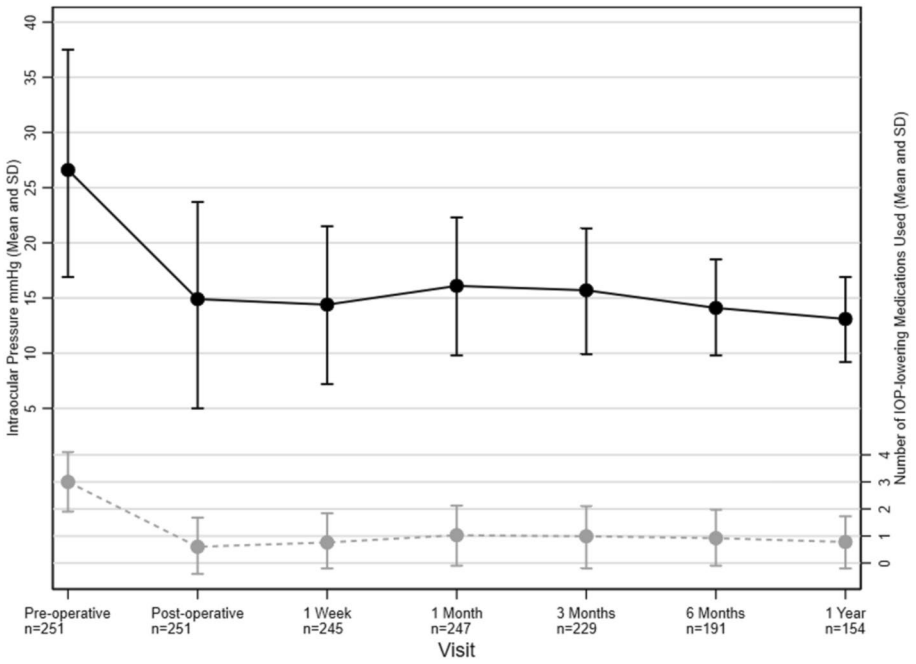

Fig. 1. Line graph showing IOP trend and trend of IOP-lowering medication use over duration of follow-up. SD: Standard Deviation. All differences between baseline IOP and each postoperative follow-up visit, as well as between baseline and each treatment count, were statistically significant ($p < 0.001$)

Visit	IOP	Number of IOP-lowering medications
Pre-operative. Mean (SD)	25.3 (8.8)	3.03 (1.12)
1 day. Mean (SD)	14.9 (9.0)	0.5 (0.94)
1 Week. Mean (SD)	14.0 (6.6)	0.61 (0.98)
1 Month. Mean (SD)	15.8 (5.1)	0.93 (1.07)
3 Months. Mean (SD)	15.3 (4.7)	0.84 (1.04)
6 Months. Mean (SD)	14.1 (4.2)	0.91 (1.04)
1 Year. Mean (SD)	13.1 (3.9)	0.78 (0.96)

Table 2. Mean intraocular pressure (IOP) and number of IOP-lowering medications before and after Paul Glaucoma Implant (PGI) surgery at each follow-up visit. Data are presented as mean ± standard deviation (SD). *SD* standard deviation.

phase was described in 42 eyes (16.7%). Three patients required additional surgery: one to relieve iris induced tube obstruction, another for additional transscleral cyclophotocoagulation for uncontrolled IOP and a third for implant plate extrusion.

Table 4 presents the results of univariable and multivariable logistic regression analyses examining the association between various preoperative, intraoperative and postoperative factors and the likelihood of achieving complete surgical success at one year. In the univariable analysis, high myopia [Odds ratio (OR): 0.50; and 95% Confidence Interval (CI): 0.30–0.85; $p = 0.010$] was significantly associated with a lower chance of success. Combined surgery with phacoemulsification (OR 3.61; CI 1.30–10.36; $p = 0.017$) and the use of antimetabolites (OR 3.24; CI 1.68–6.27; $p < 0.001$) were positively associated with success (Fig. 3A–D). In the multivariable model, after adjusting for confounding variables, the factors that remained statistically significant were: combined PGI–phacoemulsification surgery (OR 4.38; CI 1.10–17.36; $p = 0.036$); the use of intraoperative antimetabolites such as Mitomycin C (MMC) or 5-fluorouracil (5-FU) (OR 2.59; CI 1.18–5.67; $p = 0.018$), and the removal of the intraluminal ripcord, particularly after month 4 (OR 2.36; CI 1.07–5.18; $p = 0.033$). IOP decreased from 18.2 ± 6.8 mmHg before ripcord extraction to 14.5 ± 5.4 mmHg after ripcord extraction ($p < 0.001$). Regarding the use of antimetabolites, the results were consistent for both MMC and 5-FU. However, 5-FU demonstrated greater efficacy in lowering IOP during the early postoperative period, whereas MMC was associated with more pronounced IOP reductions in the later follow-up visits.

Other variables such as surgeon experience, glaucoma type, prior glaucoma surgery, and hypertensive phase did not show significant independent associations with surgical success in the adjusted model.

Figure 4 shows the OR (and 95% CI) for ripcord extraction during each postoperative visit and its relationship with complete success at 1 year follow-up. The curve demonstrates that the odds of success steadily increase in

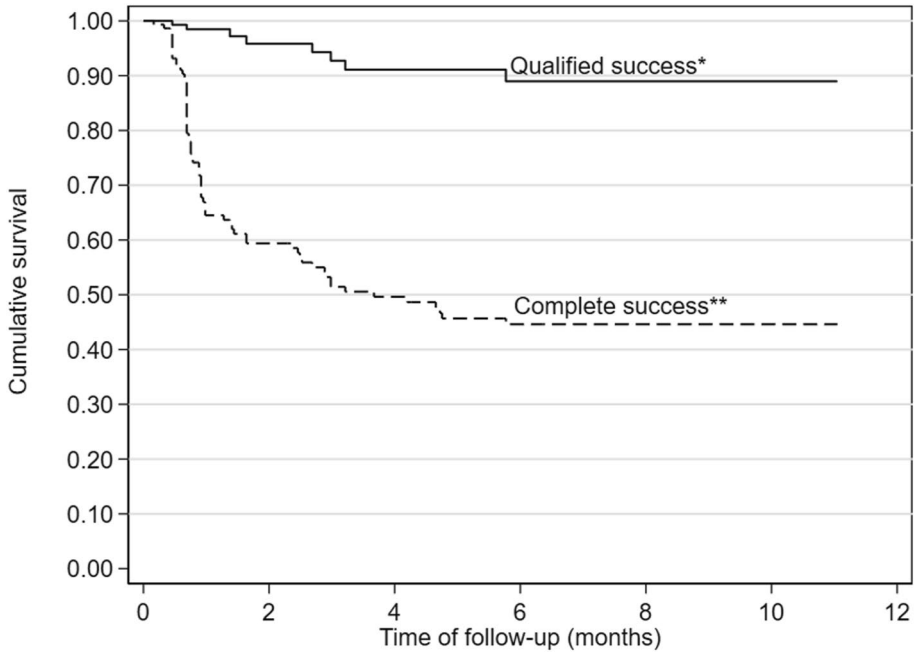

Fig. 2. Kaplan Meier Survival Curve over 1-year post-operatively. *Definition of failure: IOP > 18 mmHg or < 4 mmHg (with or without hypotensive drops) in 2 consecutive visits after the 1st month visit. **Definition of failure: IOP > 18 mmHg or ≤ 4 mmHg (without hypotensive drops) in 2 consecutive visits after the 1st month visit.

Complications	Early*	Late**
Shallow/flat anterior chamber, n (%)	6 (2.4)	1 (0.5)
Hyphema, n (%)	11 (4.4)	0
Vitreous hemorrhage, n (%)	3 (1.2)	0
Sub/conjunctival hemorrhage, n (%)	9 (3.6)	0
Fibrin membrane, n (%)	1 (0.4)	0
Corneal edema or ulcer, n (%)	10 (3.9)	1 (0.5)
Tube opening obstruction, n (%)	2 (0.8)	1 (0.5)
Hypertensive phase, n (%)	42 (16.7)	0
Other, n (%) : High IOP, extrusion, etc	44 (17.5)	21 (10.9)

Table 3. Early and late complications. *Early: visit Week 1 or Month 1. **Late: visit Month 6 or Month 12.

the first few months postoperatively, reaching a peak around the 4th to 5th month. After this point, the curve flattens, suggesting a plateau in the benefit of further delaying the ripcord removal. These findings indicate that postponing the removal of the ripcord until approximately the 4th or 5th postoperative month may optimize the hypotensive effect of the PGI while minimizing the need for additional IOP-lowering medications—thus providing practical guidance for postoperative management.

Best-corrected visual acuity (BCVA) remained overall stable during the 12-month follow-up period in the 149 eyes analyzed with complete data at 1 year (baseline: 0.45 ± 0.026; 12 months: 0.47 ± 0.027; $p = 0.237$). When stratified by surgical approach, the 127 eyes undergoing standalone PGI implantation showed no significant change in BCVA (baseline: 0.45 ± 0.029; 12 months: 0.44 ± 0.029; $p = 0.672$). In contrast, the 22 eyes that underwent combined surgery with phacoemulsification demonstrated a significant improvement in BCVA, increasing from 0.44 ± 0.057 at baseline to 0.61 ± 0.067 at 12 months ($p = 0.004$).

Discussion

The popularity of PGI has been increasing progressively in recent years and more and more publications are reporting its effectiveness and good safety profile. One of the possible reasons for its increasing acceptance is its free flow design that allows it to function from the first postoperative day. The narrower internal diameter of the tube, coupled with an intraluminal ripcord, allows immediate flow while having a pressure gradient sufficient to avoid hypotony. Thus, no ligation of the tube is necessary, as is the case with the non-valved BGD, and the risk of sudden decompression at the time of spontaneous suture lysis is avoided. Furthermore, the natural evolution

Evaluated data	Univariable OR (95%CI)	P	Multivariable OR (95%CI)	P
Surgeon experience	1.89 (0.77–4.69)	0.165	2.29 (0.77–6.85)	0.138
Myopia Magna	**0.50 (0.30–0.85)**	**0.010**	0.39 (0.12–1.24)	0.110
Non-POAG	0.66 (0.35–1.25)	0.200	0.75 (0.33–1.69)	0.568
Previous glaucoma surgery	0.81 (0.42–1.55)	0.528	0.75 (0.32–1.75)	0.491
Combined Surgery	**3.61 (1.30–10.36)**	**0.017**	**4.38 (1.10 –17.36)**	**0.036**
Antimetabolite Use	**3.24 (1.68–6.27)**	**< 0.001**	**2.59 (1.18–5.67)**	**0.018**
Hypertensive Phase	0.49 (0.24–1.03)	0.059	0.44 (0.18–1.08)	0.074
Removal of ripcord	1.65 (0.87–3.15)	0.125	**2.36 (1.07–5.18)**	**0.033**

Table 4. Results of univariable and multivariable logistic regression analyses evaluating the relationship between selected preoperative, intraoperative, and postoperative variables and the probability of achieving complete surgical success—defined as adequate intraocular pressure control without medication—at one-year follow-up. Odds ratios (OR) with 95% confidence intervals (CI) are provided to indicate the strength and significance of these associations. *Non-POAG* non–primary open-angle glaucoma, *OR* odd ratios, *CI* confidence interval.

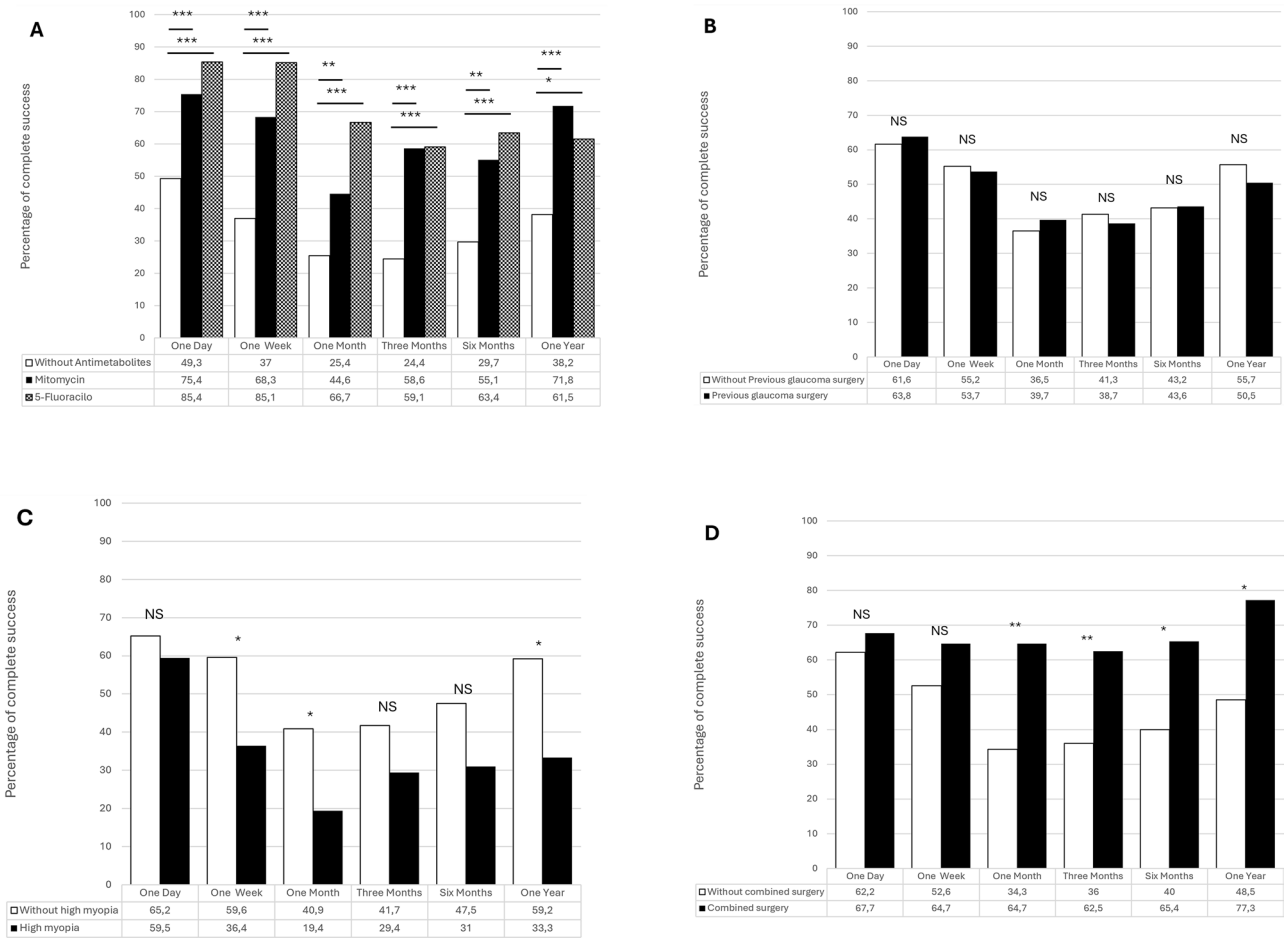

Fig. 3. Frequency of cases with complete success (IOP > 4 mm Hg and ≤ 18 mm Hg without topical hypotensive drops) in each follow-up period (* $p < 0.05$; ** $p < 0,01$; *** $p < 0.001$. NS: not statistically significant). (**A**) Use of Mitomycin C and 5-Fluoracil. (**B**) Previous glaucoma surgery. (**C**) High Myopia. (**D**) Combined surgery (Phacoemulsification + Paul Glaucoma Implant).

of surgery in recent times has been towards minimal invasiveness and this has been reflected in the advent of minimally invasive bleb surgery (MIBS) implants, promoting increasingly thinner tube designs. In this sense, PGI has followed this line by presenting a tube of smaller caliber than the previous GDDs like BGD or Ahmed ClearPath.

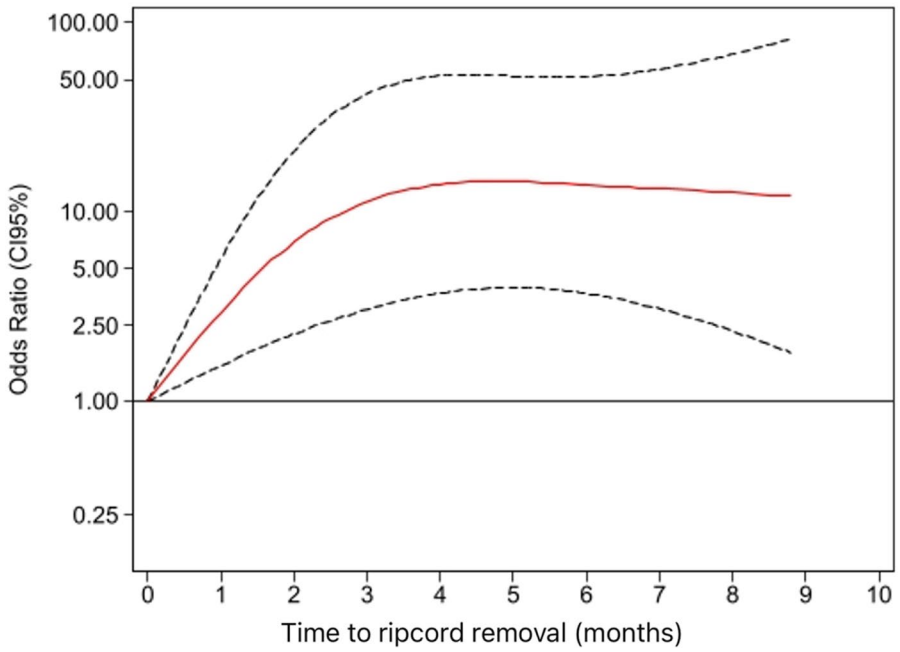

Fig. 4. Multi-adjusted* cubic regression splines to assess the association with complete success according to the timing of ripcord removal, measured in months, compared to participants who have not had their ripcord removed but require topical treatment at the 1-year visit. *Adjusted for age, sex, surgeon experience, use of antimetabolite, history of myopia magna, Open-angle glaucoma, history of previous glaucoma surgery, combined surgery, occurrence of hypertensive phase, removal of ripcord. Complete success: IOP (> 4 to ≤ 18 mmHg) and no IOP-lowering medications used.

In this multicenter study conducted in Spain we included more than 200 patients. To our knowledge, this is the largest study to date involving patients receiving a PGI. The mean decrease in IOP in our study was 48.2%, which is between the 42.9% published by Koh[8] and the 60% published by Jose[4]. And our findings are also consistent with those of Weber et al., who reported a mean IOP reduction of 43.4% and 41.5% at 1 and 2 years respectively in European cohorts undergoing PGI implantation, with a substantial decrease in medication use and a favorable safety profile[9,10]. The reduction in the number of medications was 74.2%, which is also similar to other published studies[4,8].

Our primary objective was to identify the factors associated with successful IOP control at one year of follow-up, using both univariable and multivariable analyses. One of the most significant factors found was the use of antimetabolites (MMC or 5-FU). However, the use of antimetabolites in other GDDs still remains controversial[11]. Alvarado et al. found that the adjunctive use of both intraoperative MMC and postoperative 5-FU during Ahmed valve implantation was associated with higher success rates[12], in contrast to the findings of Costa et al.[13]. Similarly, Irak et al. reported that MMC did not provide any significant benefit in BGD surgery[14], which differs from the conclusions of De Sousa et al., who reported a positive effect[15].

In MIBS such as XEN or Preserflo, antimetabolites have been effective in decreasing IOP[16,17]. Our results indicate that antimetabolites are effective in enhancing the effectiveness of PGI, more in line with the effect observed in MIBS than in traditional GDD surgeries. It should be noted that the lumen of the Paul tube is 127 microns and with a 6/0 Prolene ripcord it is reduced by about 70–80 microns, making the final internal diameter similar to XEN63 or Preserflo. This fact could mean that PGI acts in a similar way as a MIBS device to which a plate has been added to increase the filtration area. Perhaps another reason why we observe a positive effect from the use of antimetabolites in PGI surgery might be because the type of capsule formed is different from that of other classic GDDs[18], given the special design and particular functioning of PGI. The time and mechanism of maturation of the bleb of this implant is still unknown, but according to our results, it benefits from the use of intraoperative antimetabolites.

Another significant finding of this study is that PGI is more effective in combined surgery compared to solo surgery in contrast with other GDDs that tend to have worse outcomes in combined surgery. In this line, Wardani et al. found less IOP reduction with Phaco-BGD compared to solo BGD[19]. Again, our results are more similar to the ones reported with MIBS that seem to achieve better IOP results in combined surgeries. Although the exact mechanism remains unclear, combining PGI with cataract surgery may enhance the hypotensive effect, possibly due to the additional angular opening achieved through phacoemulsification and intraocular lens implantation within the capsular bag.

One of the most interesting findings of this study is the optimal timing for ripcord removal. Large-caliber nonvalved implants require a larger intraluminal ripcord to avoid severe postoperative hypotonia[20]. However, there is limited evidence on its hypotensive efficacy or the optimal time for its removal. An et al., found that

ripcord removal did not increase the success criteria for BGD, but decreased the number of hypotensive drops[21]. While some authors recommend ripcord removal between 1 and 3 months postoperatively or shortly after peritubular ligation dissolves[15,17,18], our findings suggest that the optimal timing may be around the 4th to 5th postoperative month. In clinical practice, this implies that if IOP remains suboptimal during the early postoperative period, it may be preferable to manage the patient with topical hypotensive agents and defer ripcord removal until reaching the 4–5 month window.

In our study, the frequency of the early hypertensive phase, considering this between the first and third postoperative month, was about 17%, which is lower than the 50–80% found with the BGD or Ahmed valve[22,23]. This suggests that there may be less inflammation around the plate due to slower aqueous outflow in the immediate postoperative period due to the narrower tube and ripcord. In the current study, the presence of a hypertensive phase did not influence complete success. However, some studies suggest that the hypertensive phase in other GDDs correlates with higher IOP at 1 year and greater need for postoperative medication[24,25].

Finally, in our study the trend for high myopia to be a risk factor for failure did not reach statistical significance in a multi-factor-adjusted analysis. However, we found that at 1 week, 1 month and 1 year postoperatively, the success criteria were worse than those of non-high myopia. One reason that IOP might be higher in high myopia eyes, and thus success reduced, would be that steroid elevation of IOP may be greater in high myopia. Jung et al., found that the development of hypertensive phase was significantly higher in the high-myopia group than in the non-high myopia group with Ahmed implant but with non-significant differences in cumulative probability of success at 1 year[26]. In our study, we found no significant relationship between the hypertensive phase and high myopia (OR 1.19; 95%CI 0.48–2.90, $p = 0.714$), although in all postoperative months the success criteria were lower in high myopia than in non-high myopia. One reason could be that surgeons are more reluctant to use antimetabolites in high myopic patients to avoid hypotony.

The longest follow-up study available to date on the Paul Glaucoma Implant is the retrospective review conducted by Tan et al.[27], which evaluated the 3-year outcomes in 48 eyes. The study demonstrated a sustained reduction in IOP (mean IOP of 14.9 ± 4.1 mmHg at 36 months) and a significant decrease in the number of hypotensive medications, with 75% of eyes achieving complete success. Although hypotony occurred in 17% of cases, most were self-limiting. Notably, the authors did not use internal or external tube occlusion; instead, they employed a modified flow-modulating technique called the "stability system," which involved placing a pericardial patch graft over the plate and injecting cross-linked viscoelastic beneath it to fill the reservoir and delay flow initiation. This study provides important long-term evidence supporting the efficacy and safety of the PGI. In comparison, in our series the highest rate of hypotony (IOP < 6 mmHg) was observed at the first postoperative visit (8.4%), and decreased progressively over time, with no cases recorded at 12 months. This lower and transient incidence of hypotony may be related to the use of an intraluminal ripcord in our surgical protocol, which provides immediate but controlled flow, potentially reducing the risk of early overfiltration.

One potential limitation of this study is the involvement of multiple surgeons across different centers, which may introduce variability in surgical technique and postoperative management. This includes differences in the discretionary use of postoperative medications and the timing of interventions such as needling or suture release, which could influence outcome consistency. However, this diversity also reflects real-world clinical practice, thereby enhancing the external validity and applicability of the results to a broader patient population. Additionally, the absence of a control group using other glaucoma drainage devices (GDDs) limits the ability to directly compare outcomes and contextualize the performance of the PGI within the broader range of available surgical options. Finally, the 12-month follow-up period does not allow for assessment of long-term efficacy or late complications, such as endothelial failure or device exposure, which are important considerations in evaluating the durability and safety of glaucoma implants.

In conclusion, PGI achieves significant reductions in both IOP and the number of medications after 1 year of follow-up. Our recommendations to improve IOP control with PGI would be: intraoperative use of antimetabolites, ripcord removal around 4 to 5 months postoperatively, and perform a combined surgery with phacoemulsification if needed, as these factors enhance absolute success in our study. To date, no studies have specifically addressed how to optimize the use of the PGI, and applying the same criteria used for large-caliber GDDs may not be appropriate in the case of the PGI. We believe that PGI exhibits characteristics of both MIBS in terms of safety and traditional GDDs in terms of efficacy. Finally, longer-term studies are needed to determine whether these success factors remain consistent or change over time, and to address other issues such as the type of capsule formed, its maturation time, or what factors may determine longer-term survival.

Methods

Design and data evaluated

This is a prospective multicenter study of a cohort of glaucoma patients from Spain who underwent PGI surgery with one-year prospective follow-up, initiated in March 2021. The data was extracted from the medical records of the different participating hospitals between March 2021 and January 2024. Each participating center added the study data to a REDCap (Research Electronic Data Capture) platform created for this purpose. Data included preoperative, demographic features, factors related to the surgical procedure, and postoperative evolution in the first 24 h and subsequent visits at 1 week and 1, 3, 6 and 12 months.

At the preoperative visit, sociodemographic data and medical information of patients were collected. Concerning the surgical procedure, data collected included combined or solo PGI surgery, use of antimetabolites, use of 6/0 Prolene ripcord and complications.

Mitomycin C (0.01%, 0.02%, or 0.04%) or 5-Fluorouracil was applied either via subconjunctival sponges for 2 min (followed by irrigation) or by subconjunctival injection, depending on the conjunctival, Tenon's, and scleral characteristics. MMC 0.04% was only used with sponges. Lower concentrations or 5-FU were chosen for

thin sclera like in high myopia or poor conjunctival quality, while higher concentrations were used in those with thick Tenon's or prior fibrosis.

During follow-up visits, data was collected to assess the success of the surgery (IOP and hypotensive treatments), complications, and the procedures freely chosen by surgeons for the correct evolution of the patients such as removal of the ripcord, antimetabolite injection, capsule drainage etc.

Intraoperative modifications and postoperative management were left to the experience of each surgeon, such as the choice of the ocular quadrant or the use and dosage of antimetabolites.

In the postoperative period, all patients received topical steroids for at least the first 3–4 months and the introduction of postoperative hypotensive medication was left to the discretion of each surgeon. Finally, each surgeon chose the appropriate time to remove the ripcord according to IOP evolution and the characteristics of each specific case.

Participants

A total of 251 PGI surgeries were performed by 29 glaucoma surgeons across 20 participating hospitals. The surgeons had a mean of 19.5 ± 7.7 years of experience in glaucoma surgery. Prior to the study, all surgeons received standardized training in the PGI implantation technique conducted by an experienced instructor.

The study enrolled adult patients (≥ 18 years) diagnosed with medically uncontrolled glaucoma who were scheduled for PGI implantation. Inclusion criteria comprised eyes with IOP inadequately controlled despite maximally tolerated medical therapy, with or without prior ocular surgery. Both primary and secondary types of glaucoma were eligible for inclusion.

Exclusion criteria included active ocular infection or inflammation, a history of extensive conjunctival scarring precluding device implantation, prior GDD implantation in the same eye, and insufficient follow-up data. Eyes with neovascular glaucoma, uveitic glaucoma with ongoing inflammation, or significant corneal endothelial compromise deemed at high risk for decompensation were also excluded.

Statistical analysis

Longitudinal changes in IOP and medication use were analyzed using linear mixed-effects models, accounting for within-subject correlations and missing data. Adjusted means and standard deviations (SD) were estimated for each follow-up visit.

The success of the surgery was defined as complete success (IOP between > 4 and ≤ 18 mmHg without hypotensive treatment in 2 consecutive visits after the 1st month visit) and qualified success (similar to complete success criteria, but with supplemental medical treatment). In both definitions, success also required the absence of additional glaucoma surgeries and no progression to visual loss to no light perception.

To assess the association between different variables and the complete success of the surgery after 1 year, univariant and multivariable adjusted logistic regression analyses were conducted. These results are expressed as Odds Ratios (OR) and their 95% confidence intervals (95% CI).

To evaluate the association between the timing of ripcord removal and the success of the surgery after 1 year, cubic regression splines adjusted for the same variables were used. Notably, our comparison focused on identifying the optimal timing for ripcord removal by evaluating outcomes in patients who had the ripcord withdrawn before versus those who maintained good IOP control at one year but with the ripcord still in place.

The chi-square test was used to compare the frequency of complete success according to the use of Mitomycin C and 5-Fluorouracil, history of previous glaucoma surgery, presence of high myopia, and combined surgery (phacoemulsification + PGI) over a number of follow-up periods.

Additionally, Kaplan–Meier survival curves for 1 year follow-up after IOP surgery are presented. A two-tailed p-value of < 0.05 was considered statistically significant.

Analyses were performed using STATA 17.0. The study data were collected and managed using REDCap electronic data capture tools hosted at the University of Navarra, Pamplona, Spain. This study was approved by the Ethics Committee for Research of the Hospital Clínic de Barcelona (Number HCB/2021/1106) and was accepted by the other participating hospitals. Informed consent was obtained from all subjects and/or their legal guardian(s) prior to their inclusion in the study. All procedures adhered to the principles of the Declaration of Helsinki.

Data availability

The datasets generated and analyzed during the current study are available from the corresponding author on reasonable request. Due to patient privacy considerations and institutional regulations, individual-level clinical data are not publicly shared but can be provided in de-identified form upon request for legitimate research purposes.

Received: 27 April 2025; Accepted: 1 September 2025
Published online: 03 November 2025

References

1. Gedde, S. J. et al. Treatment outcomes in the tube versus trabeculectomy (TVT) study after five years of follow-up. *Am. J. Ophthalmol.* **153**, 803.e2 (2012).
2. Gedde, S. J. et al. Treatment outcomes in the primary tube versus trabeculectomy study after 5 years of follow-up. *Ophthalmology* **129**, 1344–1356 (2022).
3. Matarazzo, F. et al. Ahmed and baerveldt in glaucoma surgery: what is the safest choice? A systematic review and meta-analysis. *Graefe's Arch. Clin. Exp. Ophthalmol.* https://doi.org/10.1007/s00417-025-06794-w (2025).

4. José, P. et al. One-year efficacy and safety of the PAUL glaucoma implant using a standardized surgical protocol. *J. Glaucoma* **31**, 201–205 (2022).
5. Vallabh, N. A. et al. Surgical technique, perioperative management and early outcome data of the PAUL® glaucoma drainage device. *Eye (Basingstoke)* **36**, 1905–1910 (2022).
6. Tan, M. C. J. et al. Two-year outcomes of the paul glaucoma implant for treatment of glaucoma. *J. Glaucoma* **31**, 449–455 (2022).
7. Carlà, M. M. et al. The Paul Glaucoma Implant: A systematic review of safety, efficacy, and emerging applications. *Graefe's Arch. Clin. Exp. Ophthalmol.* https://doi.org/10.1007/s00417-025-06861-2 (2025).
8. Koh, V. et al. Treatment outcomes using the PAUL glaucoma implant to control intraocular pressure in eyes with refractory glaucoma. *Ophthalmol. Glaucoma* **3**, 350–359 (2020).
9. Weber, C. et al. Clinical outcomes of the PAUL® glaucoma implant: One-year results. *Clin. Exp. Ophthalmol.* **51**, 566–576 (2023).
10. Weber, C., Hundertmark, S., Stasik, I., Holz, F. G. & Mercieca, K. Two-year clinical outcomes of the PAUL glaucoma implant in white patients with refractory glaucoma. *J. Glaucoma* **33**, 808–814 (2024).
11. Amoozgar, B., Lin, S. C., Han, Y. & Kuo, J. A role for antimetabolites in glaucoma tube surgery: Current evidence and future directions. *Curr. Opin. Ophthalmol.* **27**, 164–169 (2016).
12. Alvarado, J. A., Hollander, D. A., Juster, R. P. & Lee, L. C. Ahmed valve implantation with adjunctive mitomycin C and 5-fluorouracil: long-term outcomes. *Am. J. Ophthalmol.* **146**, 276–284 (2008).
13. Costa, V. P., Azuara-Blanco, A., Netland, P. A., Lesk, M. R. & Arcieri, E. S. Efficacy and safety of adjunctive mitomycin C during Ahmed Glaucoma Valve implantation: A prospective randomized clinical trial. *Ophthalmology* **111**, 1071–1076 (2004).
14. Irak, I., Moster, M. R. & Fontanarosa, J. Intermediate-term results of baerveldt tube shunt surgery with mitomycin C use. *Ophthalmic Surg. Lasers Imaging* **35**, 189–196 (2004).
15. De Sousa Peixoto, R. et al. Baerveldt Aqueous Shunt with or without Mitomycin C augmentation: A retrospective comparison study. *Ophthalmol. Glaucoma* https://doi.org/10.1016/J.OGLA.2022.11.007 (2022).
16. Galal, A., Bilgic, A., Eltanamly, R. & Osman, A. XEN Glaucoma implant with mitomycin C 1-year follow-up: Result and complications. *J. Ophthalmol.* **2017**, 5457246 (2017).
17. Barberá, M. I., Martínez-Galdón, F., Caballero-Magro, E., Rodríguez-Piñero, M. & Tañá-Rivero, P. Efficacy and safety of the preserflo microshunt with mitomycin C for the treatment of open angle glaucoma. *J. Glaucoma* **31**, 557–566 (2022).
18. Molteno, A. C. B., Fucik, M., Dempster, A. G. & Bevin, T. H. Otago glaucoma surgery outcome study: Factors controlling capsule fibrosis around molteno implants with histopathological correlation. *Ophthalmology* **110**, 2198–2206 (2003).
19. El Wardani, M., Bergin, C., Bradly, K. & Sharkawi, E. Baerveldt shunt surgery versus combined Baerveldt shunt and phacoemulsification: A prospective comparative study. *Br. J. Ophthalmol.* **102**, 1248–1253 (2018).
20. Sherwood, M. B. & Smith, M. F. Prevention of early hypotony associated with Molteno implants by a new occluding stent technique. *Ophthalmology* **100**, 85–90 (1993).
21. An, S. J. et al. Scheduled postoperative ripcord removal in baerveldt 350 implants: A prospective, randomized trial. *J. Glaucoma* **28**, 165–171 (2019).
22. Abe, R. Y., Tavares, C. M., Schimiti, R. B., Vasconcellos, J. P. C. & Costa, V. P. Ahmed glaucoma valve implantation for refractory glaucoma in a tertiary hospital in Brazil. *J. Ophthalmol.* https://doi.org/10.1155/2015/850785 (2015).
23. Fargione, R. A., Tansuebchueasai, N., Lee, R. & Tania Tai, T. Y. Etiology and management of the hypertensive phase in glaucoma drainage-device surgery. *Surv. Ophthalmol.* **64**, 217–224 (2019).
24. Özalp, O., İlgüy, S., Atalay, E., Şimşek, T. & Yıldırım, N. Risk factors for hypertensive phase after Ahmed glaucoma valve implantation. *Int. Ophthalmol.* **42**, 147–156 (2022).
25. Nouri-Mahdavi, K. & Caprioli, J. Evaluation of the hypertensive phase after insertion of the Ahmed Glaucoma Valve. *Am. J. Ophthalmol.* **136**, 1001–1008 (2003).
26. Jung, K. I. & Park, C. K. Risk factors for the hypertensive phase after implantation of a glaucoma drainage device. *Acta Ophthalmol.* **94**, e260–e267 (2016).
27. Tan, M. C. J. et al. Three-year outcomes of the Paul glaucoma implant for treatment of glaucoma. *J. Glaucoma* **33**, 478–485 (2024).

Acknowledgements

The authors thank Alejandro Fernández-Montero MD, PhD for the statistical study and statistical review of the article.

Author contributions

All authors contributed to the conception and design of the study. Elena Millá and Javier Moreno-Montañés coordinated the multicenter data collection and patient recruitment as well as data interpretation and critical revision of the manuscript. The rest of authors contributed to patients recruitment and data collection. All authors reviewed and approved the final version and agree to be accountable for all aspects of the work.

Funding

This article was financially supported by Advanced Ophthalmic Innovations and Viú20/20 to facilitate the adaptation of REDCap through which the data were collected and managed. The sponsor or funding organization had no role in the design or conduct of this research.

Competing interests

The authors declare no competing interests.

Additional information

Correspondence and requests for materials should be addressed to J.M.-M.

Reprints and permissions information is available at www.nature.com/reprints.

Publisher's note Springer Nature remains neutral with regard to jurisdictional claims in published maps and institutional affiliations.

Open Access This article is licensed under a Creative Commons Attribution-NonCommercial-NoDerivatives 4.0 International License, which permits any non-commercial use, sharing, distribution and reproduction in any medium or format, as long as you give appropriate credit to the original author(s) and the source, provide a link to the Creative Commons licence, and indicate if you modified the licensed material. You do not have permission under this licence to share adapted material derived from this article or parts of it. The images or other third party material in this article are included in the article's Creative Commons licence, unless indicated otherwise in a credit line to the material. If material is not included in the article's Creative Commons licence and your intended use is not permitted by statutory regulation or exceeds the permitted use, you will need to obtain permission directly from the copyright holder. To view a copy of this licence, visit http://creativecommons.org/licenses/by-nc-nd/4.0/.

© The Author(s) 2025

The Spain' Paul Glaucoma Implant Group (SPGG)

Elena Millá[1], Javier Moreno-Montañés[2], Susana Duch[3], Aitor Lanzagorta[4], Jesús Téllez[5], José Vicente Piá[4], Elena Arrondo[6], Jorge Vila[7], Alfonso Antón[8], Javier Bóveda[9], Jordi Loscos[10], Francesc Franquesa-Garcia[1], Mercè Perramon[1], Remei Hurtado[1], María Jesús Chaves-Samaniego[11], Lucía Rial Álvarez[11,13], Cristina Irigoyen[2], Miguel Naveiras[2], Miriam Puente[2], Angelica Freytas[12], José Belda[13], Carlos Arciniegas[14], Elena Ávila[14], Emma Ausín[15], Teresa Colas[15], Marta Castany[16], Jaume Rigo Quera[16], Julian García-Feijoo[17], José Mª Martínez Casa[17], Lucía Perucho[17], Marina Brocal Sánchez[18], Noelia Druetta[18], Natalia Olmo[19], Susana Perucho Martínez[20], Daniel Gómez Plaza[6], Julia Barreiro Honrado[9] & Martín González Vázquez[9]

[11]Vissum Miranza Group, Alicante, Spain. [12]Hospital de Manises, Valencia, Spain. [13]Hospital de Torrevieja, Alicante, Spain. [14]Innova Ocular, Verte- Barcelona, Spain. [15]Hospital Universitario Infanta Leonor, Madrid, Spain. [16]Hospital Universitari Vall d'Hebron, Barcelona, Spain. [17]Hospital Clínico San Carlos, Madrid, Spain. [18]Hospital Universitario Son Espases, Palma de Mallorca, Spain. [19]Hospital Universitario de Jaén, Jaén, Spain. [20]Hospital Universitario de Fuenlabrada, Madrid, Spain.