Actas Dermo-Sifiliográficas 117 (2026) 104496

Contents lists available at ScienceDirect

Actas Dermo-Sifiliográficas

journal homepage: www.actasdermo.org

Research Letter

Real-world Safety and Efficacy Profile of JAK Inhibitors in Pediatric Alopecia Areata: A Multicenter Retrospective Study

M. Mansilla-Polo [a,b,*], C. Abril-Pérez [a,b], L. Berbegal [c], T. Díaz-Corpas [d], A. Fernández-Arregui [e], M. Évole-Buselli [a]

[a] Departamento de Dermatología, Hospital Universitario y Politécnico La Fe, Valencia, Spain
[b] Instituto de Investigación Sanitaria La Fe (IIS La Fe), Valencia, Spain
[c] Departamento de Dermatología, Hospital General Universitario Doctor Balmis, Alicante, Spain
[d] Departamento de Dermatología, Hospital Universitario Doctor Peset, Valencia, Spain
[e] Departamento de Dermatología, Hospital Clínico Universitario, Valencia, Spain

To the Editor,

Alopecia areata (AA) is a non-scarring autoimmune alopecia.[1] Beyond follicular damage, it has a significant impact on the patients' quality of life, a particularly relevant aspect in the pediatric population, where social acceptance plays a crucial role in emotional development.[2]

In recent years, three Janus kinase inhibitors (JAK inhibitors, iJAKs) have been approved for the treatment of AA: baricitinib, deuruxolitinib, and ritlecitinib, the latter being the only one approved for pediatric patients aged 12–18 years.[3]

However, studies in pediatric populations remain scarce, especially in real-world clinical settings or direct drug comparisons.

We conducted a retrospective multicenter study in four hospitals in the Valencian Community, including pediatric patients (<18 years) with AA treated with iJAKs through December 2024. Only the first iJAK administered to each patient was considered. Baseline characteristics, safety, and efficacy were collected using validated scales: the Severity of Alopecia Tool (SALT) for scalp involvement, the Eyebrow Assessment Scale (EBA), and the Eyelash Assessment Scale (ELA).

A total of 17 patients were included (9 on baricitinib, 7 on tofacitinib, and 1 on ritlecitinib). Males accounted for 46.7% of the cohort, with a median age of 13 years (range, 2–17) at initiation of iJAK therapy and a median course of the disease of 56 months (range, 3–120).

Most patients exhibited a high disease burden, with alopecia universalis being the most frequent subtype (58.8%), and along with alopecia totalis accounting for 76.4% of the cohort. More than 80% of patients had eyebrow and eyelash involvement. All had received prior treatments, and >75% had undergone ≥3 therapeutic lines prior to iJAK initiation.

The median baseline SALT score was 80 (range, 3–100), which progressively dropped down to 1.5 (range, 0–18) at weeks 48–52, remaining stable in patients followed beyond 1 year (up to 72 weeks) (Fig. 1 and Supplementary Fig. 1). A total of 88.2% (14/17) of patients achieved an adequate response (SALT <20), and 76.5% (13/17) achieved SALT <2 during follow-up. Similar improvements were observed in the EBA and ELA scales, with most patients reaching the maximum score of 3 (complete regrowth) within the same timeframe. The safety profile of iJAKs was favorable. Six patients (35.3%) – 3 on baricitinib and 3 on tofacitinib – experienced mild adverse events, including acne, impetigo, and abdominal pain. All events were classified as mild and possibly treatment-related (Tables 1 and 2).

We present a multicenter study suggesting the effectiveness safety and efficacy profile of iJAKs, primarily baricitinib and tofacitinib, in pediatric AA. Notably, this cohort was characterized by patients with high disease burden, frequent total and universal forms, and multiple prior treatments, likely reflecting their use in refractory, heavily pretreated cases. Additionally, the relatively high number of patients on tofacitinib reflects its prescription prior to the approval of baricitinib and ritlecitinib.

Until recently, treatment options for AA were largely limited to classic immunosuppressants such as systemic corticosteroids, cyclosporine, or methotrexate – agents with limited efficacy and frequent side effects.[4] However, the discovery within the past decade of the role of the JAK pathway in the pathogenesis and maintenance of AA led to the approval by the European Medicines Agency (EMA) and U.S. Food and Drug Administration (FDA) of baricitinib (4 mg/day in patients ≥18 years)[5] and ritlecitinib (50 mg/day in patients ≥12 years).[6] Recently, deuruxolitinib, another JAK1/JAK2 inhibitor, has been approved by the FDA for patients ≥18 years.[7] The approval of ritlecitinib in adolescents was based on the phase IIb/III ALLEGRO trial, which reported SALT ≤20 in 50% of patients at week 48, with an acceptable safety profile.[6] Evidence for baricitinib in pediatric patients remains limited, though 1 case has described its efficacy and tolerability in a 17-year-old patient.[8] Baricitinib is currently under investigation in a phase III clinical trial (BRAVE-AA-PEDS) for children aged 6–18 years with severe AA. At the same time, multiple series have supported the off-label use of tofacitinib in pediatric populations due to its safety and efficacy,[9] despite its lack of formal approval or ongoing trials. These data have led recent European clinical practice guidelines to position iJAKs as first-line therapy for severe AA (SALT >20).[10] Supplementary Table 1[8,11–39] illustrates the main studies evaluating iJAKs for AA in real-world clinical practice.

* Corresponding author.
E-mail address: miguel_yecla96@hotmail.com (M. Mansilla-Polo).

https://doi.org/10.1016/j.ad.2025.104496

0001-7310/© 2025 AEDV. Published by Elsevier España, S.L.U. This is an open access article under the CC BY-NC-ND license (http://creativecommons.org/licenses/by-nc-nd/4.0/).

Table 1
Baseline characteristics of patients and disease.

	Overall (n = 17)	1st iJAK baricitinib (n = 9)	1st iJAK tofacitinib (n = 7)	1st iJAK ritlecitinib (n = 1)
Baseline patient characteristics at initiation of 1st iJAK				
Male sex, n (%)	7 (46.7)	3 (33.3)	3 (42.9)	1 (100)
Current age (December 2024), median (range)	14 (5–23)	14 (9–19)	17 (9–23)	14
Age at iJAK initiation, median (range)	13 (2–17)	10 (2–16)	14 (12–17)	13
Weight at iJAK initiation (kg), median (range)	44 (13–87)	41 (15–87)	46 (13–67)	58
Height at iJAK initiation (cm), median (range)	147 (112–183)	135 (112–183)	156 (145–174)	180
Autoimmune comorbidities, n (%), which	3 (17.6) • Autoimmune hypothyroidism (3 patients) • Prediabetes (1 patient)	2 (22.2) •Autoimmune hypothyroidism (2 patients)	1 (14.3) • Autoimmune hypothyroidism and prediabetes (same patient)	0
Non-autoimmune comorbidities, n (%), which	5 (29.4) • Atopic dermatitis (3) • Allergic rhinoconjunctivitis (1) • Anal fistula (1) • Intellectual disability (1)	4 (44.4) • Atopic dermatitis (3) • Allergic rhinoconjunctivitis (1) • Anal fistula (1)	0	1 (100) • Intellectual disability
Cardiovascular risk factors*, n (%), which	1 (5.9) • Obesity (1)	1 (11.1) • Obesity (1)	0	0
Other relevant history**	0	0	0	0
Baseline disease characteristics at initiation of 1st iJAK				
Disease duration to iJAK start, months, median (range)	56 (3–120)	72 (48–86)	45 (3–72)	120
Prior spontaneous or pharmacologic regrowth before iJAK, n (%)	3 (17.6)	2 (22.2)	0	1 (100)
Prior treatments before iJAK, n (%)	• Any: 17 (100) • ≥3 treatments: 13 (76.5) • TCS: 14 (82.4) • ILCS: 6 (35.3) • Prednisone: 4 (23.5) • Steroid pulses: 7 (41.2) • Topical MNX: 7 (41.2) • Oral MNX: 4 (23.5) • DPCP: 8 (47.1) • CyA: 3 (17.6) • MTX: 7 (41.2) • Dupilumab: 1 (5.9)	• Any: 9 (100) • ≥3 treatments: 8 (88.8) • TCS: 7 (77.7) • ILCS: 4 (44.4) • Prednisone: 1 (11.1) • Steroid pulses: 5 (55.5) • Topical MNX: 4 (44.4) • Oral MNX: 2 (22.2) • DPCP: 5 (55.5) • CyA: 1 (11.1) • MTX: 3 (33.3) • Other: 0	• Any: 7 (100) • ≥3 treatments: 5 (71.4) • TCS: 6 (85.7) • ILCS: 2 (28.6) • Prednisone: 3 (42.9) • Steroid pulses: 2 (28.6) • Topical MNX: 3 (42.9) • Oral MNX: 2 (28.6) • DPCP: 2 (28.6) • CyA: 2 (28.6) • MTX: 4 (57.1) • Dupilumab: 1 (14.3)	• Any: 1 (100) • ≥3 treatments: 0 (0) • TCS: 1 (100) • ILCS: 1 (100) • Prednisone: 0 (0) • Steroid pulses: 0 (0) • Topical MNX: 0 (0) • Oral MNX: 0 (0) • DPCP: 1 (100) • CyA: 0 (0) • MTX: 0 (0) • Other: 0 (0)
Alopecia areata subtype, n (%)	• Patchy: 4 (23.5) • Totalis: 3 (17.6) • Universalis: 10 (58.8)	• Patchy: 3 (33.3) • Totalis: 2 (22.2) • Universalis: 4 (44.4)	• Patchy: 1 (14.2) • Totalis: 0 (0) • Universalis: 6 (85.8)	• Patchy: 0 (0) • Totalis: 1 (100) • Universalis: 0 (0)
Eyebrow involvement, n (%)	14 (82.4)	6 (66.6)	7 (100)	1 (100)
Eyelash involvement, n (%)	15 (88.2)	7 (77.7)	7 (100)	1 (100)
Beard involvement, n (%)***	3 (75)	1 (100)	2 (100)	0 (0)

ILCS: intralesional corticosteroids; TCS: topical corticosteroids; CyA: cyclosporine A; DPCP: diphenylcyclopropenone; iJAK: Janus kinase inhibitor; MNX: minoxidil; MTX: methotrexate.

* Includes obesity, hypertension, diabetes mellitus, dyslipidemia.

** Includes tobacco, alcohol, use of hormonal contraceptives, skin cancer, solid-organ or hematopoietic stem-cell transplant, viral hepatitis, human immunodeficiency virus.

*** Applicable only to female patients and post-pubertal boys (criterion met by 4 patients in total: 2 on tofacitinib, 1 on baricitinib, and the ritlecitinib patient).

Table 2
Safety and efficacy of iJAKs in our series.

	Overall (n = 17)	1st iJAK baricitinib (n = 9)	1st iJAK tofacitinib (n = 7)	1st iJAK ritlecitinib (n = 1)
Initial dose, n (%)	–	2 mg q24h: 3 (33.3); 4 mg q24h: 6 (66.6)	5 mg q24h: 3 (42.9); 5 mg q12h: 4 (57.1)	50 mg q24h: 1 (100)
Dose escalation during treatment for nonresponse*, n (%)	–	0 (0)	3 (42.9)	0 (0)
Treatment duration, months, median (range)	35 (1–72)	50 (23–72)	23 (1–52)	5
Response**, n (%)	• NR: 2 (11.8) • PR: 0 • CR: 13 (76.5) • PR/CR with secondary failure: 1 (5.9) • Not evaluable: 1 (5.9)	• NR: 2 (22.2) • PR: 0 (0) • CR: 6 (66.6) • PR/CR with secondary failure: 0 (0) • Not evaluable: 1 (11.1)	• NR: 0 (0) • PR: 0 (0) • CR: 6 (85.7) • PR/CR with secondary failure: 1 (14.3) • Not evaluable: 0 (0)	• NR: 0 (0) • PR: 0 (0) • CR: 1 (100) • PR/CR with secondary failure: 0 (0) • Not evaluable: 0 (0)
Time to response, months, mean (SD)	1.7 (0.9)	2.2 (1.1)	1.4 (0.5)	1.5 (0)
Dose reduction for good response, n (%)	3 (17.6)	0 (0)	3 (42.9)	0 (0)
Concomitant therapy with iJAK, n (%), type	6 (35.3): • Topical minoxidil: 1 (5.9) • Oral minoxidil: 3 (17.6) • Minoxidil + steroid injections: 2 (11.8)	2 (22.2): • Topical minoxidil: 1 (11.1) • Oral minoxidil: 1 (11.1)	4: • Oral minoxidil: 2 (28.6) • Minoxidil + steroid injections: 2 (28.6)	0
Any adverse event, n (%) and type	6 (35.3): • Symptomatic ↑CK: 2 (11.8) • Acne: 1 (5.9) • Impetigo: 1 (5.9) • Abdominal pain: 1 (5.9) • Seborrheic dermatitis: 1	3 (33.3): • Symptomatic ↑CK: 1 (11.1) • Abdominal pain: 1 (11.1) • Seborrheic dermatitis: 1 (11.1)	3 (42.9): • Symptomatic ↑CK: 1 (14.3) • Acne: 1 (14.3) • Impetigo: 1 (14.3)	0
Time to adverse event, months, median (range)	3 (2–13)	3 (2–10)	6 (4–13)	–
Continuation of first iJAK at data cutoff***, n (%), reason for discontinuation	14 (82.4): • Inefficacy and switch to iJAK: 1 (11.8) • Sustained complete response: 1 (11.8) • Adverse events: 1 (11.8)	8 (88.9): • Adverse events: 1 (11.1)	5 (71.4): • Inefficacy and switch to iJAK: 1 (14.3) • Sustained complete response: 1 (14.3)	1 (100)

CK: creatine kinase; EBA: Eyebrow Assessment Scale; ELA: Eyelash Assessment Scale; iJAK: Janus kinase inhibitor; NR: no response; CR: complete response; PR: partial response; wk: week; SALT: Severity of Alopecia Tool.

* Applicable when starting below the maximum dose (baricitinib 4 mg q24h; tofacitinib 10 mg q12h; ritlecitinib 50 mg q24h).

** CR (complete response): SALT <2 without secondary failure during follow-up; PR (partial response): improvement from baseline SALT but without achieving SALT <2 during follow-up; NR (no response): no SALT improvement during follow-up; PR/CR with secondary failure: initial SALT improvement with subsequent worsening; not evaluable: follow-up <4–8 weeks.

*** Data cutoff: December 20th, 2024.

The present study has several limitations. First, its retrospective design inherently carries limitations. Second, the small sample size and multiple observations prevented direct comparisons across drugs. Nonetheless, in our cohort, baricitinib and tofacitinib showed comparable safety and efficacy overall. Similarly, the small sample did not allow us to draw any conclusions on key clinical decisions such as dose adjustment, tapering strategies, or concomitant therapies.

Lastly, certain variables – such as nail involvement, patient preferences and satisfaction, and psychological well-being (particularly important in pediatric patients) – were not recorded.

In conclusion, this multicenter series suggests that JAK inhibitors are safe and effective treatments for pediatric AA, producing significant regrowth on the scalp, eyebrows, and eyelashes with only mild adverse effects. Further prospective studies with larger sample sizes and longer follow-up are warranted to confirm these findings.

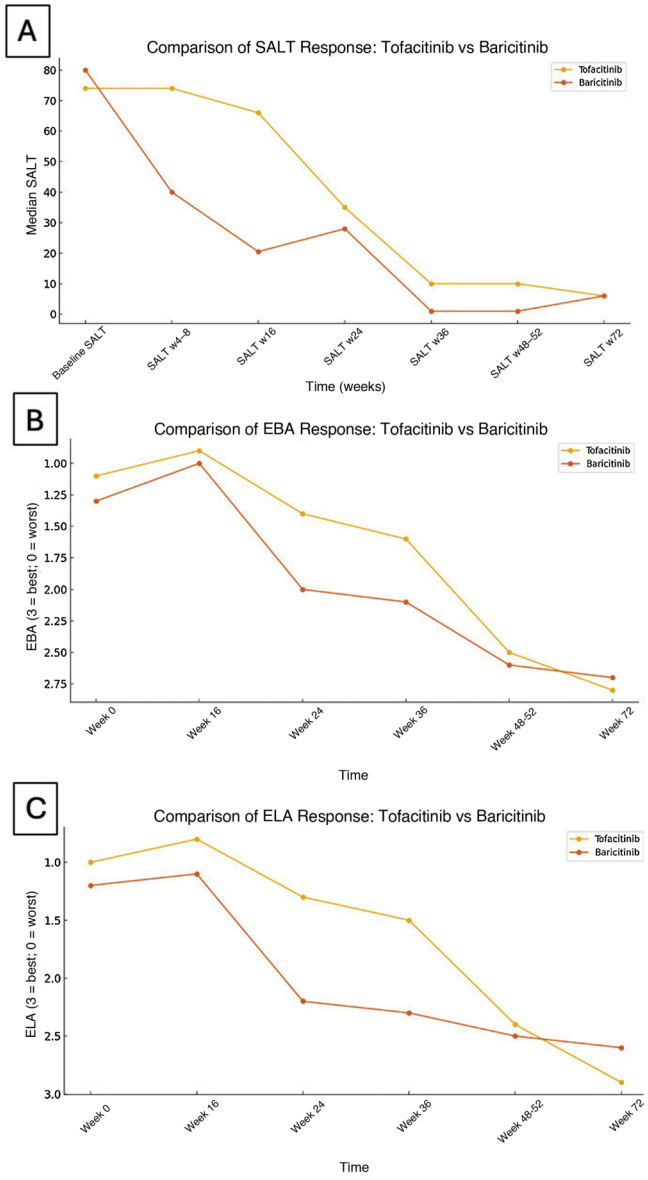

Fig. 1. Evolution of SALT (panel A), EBA (panel B), and ELA (panel C) in patients on baricitinib and tofacitinib in our cohort. EBA: Eyebrow Assessment Scale; ELA: Eyelash Assessment Scale; SALT: Severity of Alopecia Tool.

Appendix A. Supplementary data

Supplementary data associated with this article can be found in the online version available at https://doi.org/10.1016/j.ad.2025.104496.

References

1. Sibbald C. Alopecia areata: an updated review for 2023. *J Cutan Med Surg*. 2023;27:241–259.
2. Sejdiu Z, Hess S, Jafferany M. Psychosocial comorbidities in patients with paediatric alopecia areata: a literature review. *Clin Exp Dermatol*. 2024;49:1118–1124.
3. Pinto-Pulido EL, García-Verdú E, Vega-Díez D. RF – Un update on the management of alopecia areata. *Actas Dermosifiliogr*. 2025;116:T423–T424.
4. Luo W-R, Shen G, Yang L-H, Zhu X-H. A bibliometrics of the treatment of alopecia areata in the past twenty years. *Dermatology*. 2024;240:42–58.
5. King B, Ohyama M, Kwon O, et al. Two phase 3 trials of baricitinib for alopecia areata. *N Engl J Med*. 2022;386:1687–1699.
6. Hordinsky M, Hebert AA, Gooderham M, et al. Efficacy and safety of ritlecitinib in adolescents with alopecia areata: results from the ALLEGRO phase 2b/3 randomized, double-blind, placebo-controlled trial. *Pediatr Dermatol*. 2023;40:1003–1009.
7. King B, Senna MM, Mesinkovska NA, et al. Efficacy and safety of deuruxolitinib, an oral selective Janus kinase inhibitor, in adults with alopecia areata: results from the phase 3 randomized, controlled trial (THRIVE-AA1). *J Am Acad Dermatol*. 2024;91:880–888.
8. Jabbari A, Dai Z, Xing L, et al. Reversal of alopecia areata following treatment with the JAK1/2 inhibitor baricitinib. *EBioMedicine*. 2015;2:351–355.
9. Westerkam LL, McShane DB, Nieman EL, Morrell DS. Treatment options for alopecia areata in children and adolescents. *Paediatr Drugs*. 2024;26:245–257.
10. Rudnicka L, Arenbergerova M, Grimalt R, et al. European expert consensus statement on the systemic treatment of alopecia areata. *J Eur Acad Dermatol Venereol*. 2024;38:687–694.
11. Bayart CB, DeNiro KL, Brichta L, Craiglow BG, Sidbury R. Topical Janus kinase inhibitors for the treatment of pediatric alopecia areata. *J Am Acad Dermatol*. 2017;77:167–170.
12. Craiglow BG, Tavares D, King BA. Topical ruxolitinib for the treatment of alopecia universalis. *JAMA Dermatol*. 2016;152:490–491.
13. Castelo-Soccio L. Experience with oral tofacitinib in 8 adolescent patients with alopecia universalis. *J Am Acad Dermatol*. 2017;76:754–755.
14. Putterman E, Castelo-Soccio L. Topical 2% tofacitinib for children with alopecia areata, alopecia totalis, and alopecia universalis. *J Am Acad Dermatol*. 2018;78:1207–1209.
15. Brown L, Skopit S. An excellent response to tofacitinib in a pediatric alopecia patient: a case report and review. *J Drugs Dermatol*. 2018;17:914–917.
16. Patel NU, Oussedik E, Grammenos A, Pichardo-Geisinger R. A case report highlighting the effective treatment of alopecia universalis with tofacitinib in an adolescent and adult patient. *J Cutan Med Surg*. 2018;22:439–442.
17. Liu LY, King BA. Ruxolitinib for the treatment of severe alopecia areata. *J Am Acad Dermatol*. 2019;80:566–568.
18. Berbert Ferreira R, Ferreira SB, Scheinberg MA. An excellent response to tofacitinib in a Brazilian adolescent patient with alopecia areata: a case report and a review of the literature. *Clin Case Rep*. 2019;7:2539–2542.
19. Rachubinski AL, Estrada BE, Norris D, Dunnick CA, Boldrick JC, Espinosa JM. Janus kinase inhibition in Down syndrome: 2 cases of therapeutic benefit for alopecia areata. *JAAD Case Rep*. 2019;5:365–367.
20. Craiglow BG, King BA. Tofacitinib for the treatment of alopecia areata in preadolescent children. *J Am Acad Dermatol*. 2019;80:568–570.
21. Dai YX, Chen CC. Tofacitinib therapy for children with severe alopecia areata. *J Am Acad Dermatol*. 2019;80:1164–1166.
22. Peterson DM, Vesely MD. Successful treatment of alopecia totalis with ruxolitinib in a preadolescent patient. *JAAD Case Rep*. 2020;6:257–259.
23. Jerjen J, Meah R, Trindade de Carvalho N, Wall L, Eisman D, Sinclair SR. Treatment of alopecia areata in pre-adolescent children with oral tofacitinib: a retrospective study. *Pediatr Dermatol*. 2021;38:103–108.
24. Wang Y, Liu T, Li S, et al. Efficacy and safety of baricitinib in patients with refractory alopecia areata. *Dermatol Ther*. 2022;35, e15845.
25. Husein-ElAhmed H, Abdulla N, Al-Obaidli A, Ali-Alam M, Steinhoff M. Real-world experience and long-term evaluation of tofacitinib in refractory alopecia areata: a prospective, open-label, single-center study in Asian Arab population. *Dermatol Ther*. 2022;35, e15871.
26. Kibbie J, Kines K, Norris D, Dunnick CA. Oral tofacitinib for the treatment of alopecia areata in pediatric patients. *Pediatr Dermatol*. 2022;39:31–34.
27. Sardana K, Mathachan SR, Gupta P. Pertinent role of maintenance dose of oral tofacitinib in a child with alopecia totalis with a 2.5-year follow-up on low dose. *J Cosmet Dermatol*. 2022;21:4091–4094.
28. McKenzie PL, Castelo-Soccio L. Alopecia areata flare patterns in children and young adults while on systemic tofacitinib. *J Am Acad Dermatol*. 2022;86:683–685.
29. Gori N, Cappilli S, Di Stefani A, Tassone F, Chiricozzi A, Peris K. Assessment of alopecia areata universalis successfully treated with upadacitinib. *Int J Dermatol*. 2023;62:e61–e63.
30. Asfour L, Getsos Colla T, Moussa A, Sinclair RD. Concurrent chronic alopecia areata and severe atopic dermatitis successfully treated with upadacitinib. *Int J Dermatol*. 2022;61:e416–e417.
31. Cantelli M, Martora F, Patruno C, Nappa P, Fabbrocini G, Napolitano M. Upadacitinib improved alopecia areata in a patient with atopic dermatitis: a case report. *Dermatol Ther*. 2022;35, e15346.
32. Youssef S, Bordone LA. Clinical response to oral tofacitinib in pediatric patients with alopecia areata. *JAAD Case Rep*. 2022;31:83–88.
33. Kołcz K, Żychowska M, Sawińska E, Reich A. Alopecia universalis in an adolescent successfully treated with upadacitinib – a case report and review of the literature on the use of JAK inhibitors in pediatric alopecia areata. *Dermatol Ther (Heidelb)*. 2023;13:843–856.
34. Huang J, Li T, Tan Z, et al. Effectiveness of tofacitinib in pre-adolescent alopecia areata: a retrospective case series and literature review. *Acta Derm Venereol*. 2023;103, adv13418.
35. Tembunde Y, Kindred C. Ruxolitinib 1.5% topical cream for the treatment of pediatric alopecia areata. *J Drugs Dermatol*. 2024;23:378–379.
36. Gowda G, Aggarwal SK, Thakur A, et al. Tofacitinib in pediatric alopecia areata totalis and alopecia universalis: a retrospective analysis from India. *J Cutan Med Surg*. 2024;28:497–502.
37. López de Hontanar Torres G, Zubicaray J, Sebastián E, Hernández-Martín A, Iriondo J, Sevilla J. Baricitinib in pediatric chronic immune thrombocytopenia and associated autoimmune conditions: a case report. *Front Pediatr*. 2024;12, 1516039.
38. Wang S, Xu Z, Zhu X, et al. Case Report: Baricitinib improved alopecia areata in a pediatric patient with atopic dermatitis. *Front Pediatr*. 2025;12, http://dx.doi.org/10.3389/fped.2024.1497285, 1497285 [PMID: 39867699; PMCID: PMC11760602].
39. Valido K, Craiglow BG. Baricitinib and oral minoxidil for the treatment of alopecia areata in pediatric patients. *J Am Acad Dermatol*. 2025;93:509–510.