JPRAS Open 48 (2026) 269–280

Contents lists available at ScienceDirect

JPRAS Open

journal homepage: www.elsevier.com/locate/jpra

Review Article

S.W.A.T. flap in plastic surgery: The latissimus dorsi. In-depth overview of a classic weapon and systematic review of its reported uses.

Belén Andresen-Lorca[a,b,*], Alessandro Thione[a], María García-García[a], Iván Heredia-Alcalde[a], Alberto Pérez-García[a], Alfonso Amador Valverde-Navarro[a], María D Pérez-del-Caz[a]

[a] Department of Plastic Surgery and Burns, University and Polytechnic Hospital La Fe, Valencia, Spain
[b] Department of Human Anatomy and Embryology, Universitat de València, Valencia, Spain

ARTICLE INFO

Article history:
Received 5 July 2025
Accepted 31 August 2025
Available online 12 September 2025

Keywords:
Latissimus dorsi flap
Reconstructive microsurgery
Functional reconstruction
Defect coverage
Uses of latissimus dorsi flap

ABSTRACT

The latissimus dorsi (LD) flap deserves recognition as the "S.W.A.T. flap" in reconstructive surgery, as a reflex of its unparalleled versatility and adaptability in addressing complex, high-risk reconstructive challenges. Much like the special intervention units we propose it to be named after, the LD flap offers a wide range of strategies that allow us to tailor it to fit virtually any defect in the human body, making it a cornerstone of reconstructive surgery.
This flexibility is supported by various features. The multiple dissection techniques and patient positioning options available enhance its utility in multi-disciplinary settings. Also, it can be harvested with different tissue compositions, such as muscle, skin, bone, and adipose tissue, providing surgeons with numerous configurations suited for diverse anatomical and functional needs. Moreover, the consistency of the thoracodorsal pedicle, allows for multiple vascular configurations and the creation of composite or chimeric flaps, making it highly adaptable to complex defect reconstructions. Furthermore, the LD flap is easily elevated with minimal

* Corresponding author.
E-mail address: beanlor@alumni.uv.es (B. Andresen-Lorca).

https://doi.org/10.1016/j.jpra.2025.08.037
2352-5878/© 2025 The Authors. Published by Elsevier Ltd on behalf of British Association of Plastic, Reconstructive and Aesthetic Surgeons. This is an open access article under the CC BY-NC-ND license (http://creativecommons.org/licenses/by-nc-nd/4.0/)

donor-site morbidity, making it an attractive option for both functional and aesthetic restoration.
To demonstrate the broad applications of the LD flap, a systematic review following PRISMA guidelines was conducted. The review aimed to identify and synthesize reported cases of the flap's use across a variety of clinical scenarios, yielding articles detailing its use in diverse anatomical regions.
This article highlights the LD flap's essential role in modern reconstructive surgery, advocating for its recognition as the "S.W.A.T. flap" due to its exceptional versatility, reliability, and broad applicability.
© 2025 The Authors. Published by Elsevier Ltd on behalf of British Association of Plastic, Reconstructive and Aesthetic Surgeons. This is an open access article under the CC BY-NC-ND license (http://creativecommons.org/licenses/by-nc-nd/4.0/)

Introduction

The acronym S.W.A.T., which stands for "special weapons and tactics," is used to design the U.S.'s special intervention units, specifically trained to resolve difficult, high-risk situations.[1] Reconstructive surgery could somehow be compared to working under these conditions, in the sense that we constantly encounter complex cases that need an effective solution, many times with just one shot left.

For the most part, one might have been in a similar scenario before, but for others, it maybe one's first time confronting that enemy. Either way, in most cases, an appropriate use of the primary weapons in our reconstructive armamentarium will bring us victory.

According to us, the most paradigmatic representation of this fact would be the latissimus dorsi flap. Its extraordinary versatility makes it appropriate for virtually any defect in each part of the human body. Of course, it will not be the most ideal solution for every single situation, but it definitely is an acceptable strategy to conquer practically all battles one may encounter in their daily practice. For this reason, it ought to be recognized as the "S.W.A.T. flap."

The Latissimus Dorsi (LD) is one of the oldest flaps in our toolbox. The possibility of using this muscle as a flap can be tracked as early as the 16th century, with Vesalius' drawings demonstrating its division from origin and lateral rotation.[2] It is Iginio Tansini, though, who deserves recognition for being the first to describe its use as a flap in breast reconstruction.[3–5] As for many techniques, it was later forgotten, only to be re-described by Olivari in 1976 for the coverage of large radiation ulcers of the chest wall.[6] The years to follow witnessed several advancements in LD flap reconstruction: Bostwick developed the principle for an island-based LD flap in breast reconstruction,[2] Quillen described its use in head and neck reconstruction,[7] and Maxwell was the first to use it as a free flap for scalp reconstruction.[8] Later, may reported its use as a free flap in lower limb reconstruction, and Bailey did similarly for the hand.[9,10] Further refining of microsurgical concepts have led to the expansion and diversification of its use over the past 40 years.[11]

Its historical evolution until consolidating as one of our main "workhorse flaps," resisting as arguably one of the most performed flaps in the era of perforator-based ones, is not a fortuity. Latissimus Dorsi offers us countless options, starting from the various techniques available for its elevation and multiple purposes it may be used for, going through the versatility of its pedicle (with diverse configurations possible) and ending with a wide range of potential compositions.

This quality of offering virtually infinite possibilities on the battlefield is what any fighter would demand from a weapon if they ought to choose just one, supporting our recognition of the LD flap as the most "Special" of "Weapons and Tactics" (S.W.A.T.) available in plastic reconstructive surgery.

In the following lines, we will offer an in-depth analysis of the abovementioned attributes.

The "countless options" flap

The latissimus dorsi flap offers us virtually "countless" possibilities. It is versatile in very many ways: harvest position, pedicle configuration, flap composition and modes of application (free or pedicled, innervated or not, functional or for coverage).

1. Dissection technique
   The latissimus dorsi muscle and all other flaps based on the thoracodorsal pedicle can be harvested in all lateral, prone or supine positions. However, most surgical manuals describe its raising only in a lateral decubitus position[11,12] and many authors still point out at meetings and congresses that one of the main limitations of this flap is its inconvenience for double-team work, given this constraint.
   Truth is, although originally described in lateral decubitus, many surgeons routinely elevate it in a supine position. This allows for a significantly easier and faster elevation compared to that of lateral or prone positions, with enhanced access and exposure to the thoracodorsal pedicle and elimination of the need for a position change.[13]
   Our team at Hospital La Fe systematically harvests flaps based on the thoracodorsal system in the supine position, owing to the previously mentioned advantages. The patient is positioned supine on the operating table, with shoulder and hip rolls placed to slightly elevate their body. Initially, the arm is left free to facilitate proper sterile draping, after which it is secured to a fixed pole at the level of the patient's head, with the shoulder fully extended and the elbow flexed to 90°, once draping is completed (Figure 1). The arm is then wrapped in a sterile bandage and fixed to a Mayo stand using Backhaus forceps (or an equivalent instrument). This positioning allows, during the final stages of dissection (particularly when elevating the medial border of the muscle), the arm



Figure 1. Supine position. The arm is draped in a sterile bandage and secured to the Mayo pole using a Backhaus forceps, with the shoulder fully extended and the elbow flexed 90°.

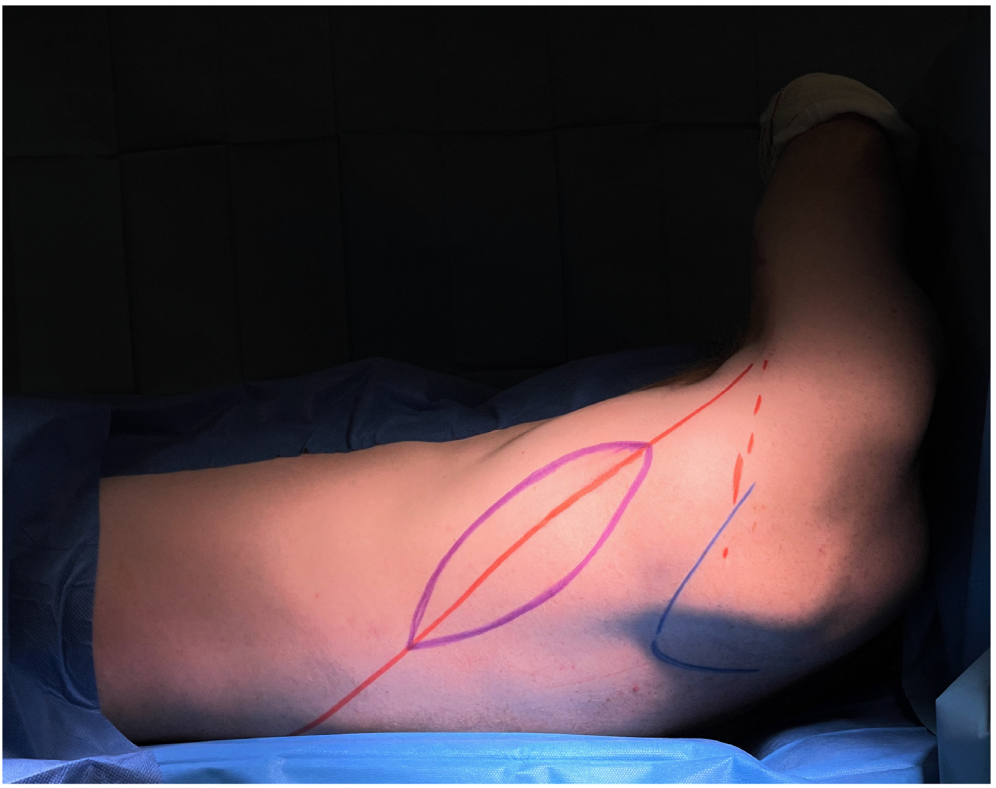

Figure 2. The arm is left free and rotated medially by an aid at the end of elevation for exposure and dissection of the medialmost aspect of the muscle.

to remain free, enabling assistance in rotating it over the torso and thereby improving exposure (Figure 2).

Consequently, "position" should no longer be a reason to rule out the LD when building our reconstructive scheme. Indeed, the possibility of harvesting this flap in any possible patient positioning might be one of its greatest virtues. It will be highly valued by any reconstructive surgeon when having to work jointly with other surgical specialties and adapt to their needs, which is very frequently the case.

The last years have seen a further evolution in the elevation of this flap, with the introduction of endoscopic latissimus dorsi dissection, which allows for a near-to scarless procedure and therefore substantial reduction in donor site morbidity.[14] Of course, this is only applicable for muscle-only flaps, mainly for cases of breast reconstruction using pedicled flaps,[15,16] although the technique has also been described in harvesting free flaps. In this last case, only small muscle flaps can be elevated, as they need to be delivered through a fairly small axillary incision; otherwise, the utilization of the endoscope would be of limited significance.[17–19]

More recently, robot-assisted latissimus dorsi flap harvesting was introduced. Indeed, minimally invasive surgical techniques are being increasingly adopted worldwide, owing to less complication rates.[20] For this particular case (latissimus dorsi flap harvest), the use of robotic techniques was first reported by Selber et al.[21] Since then, various other groups have published their experience,[22–25] showing encouraging reported outcomes, mainly regarding cosmetic results and wound-associated complications. However, total cost and the difficulty of reaching the learning curve

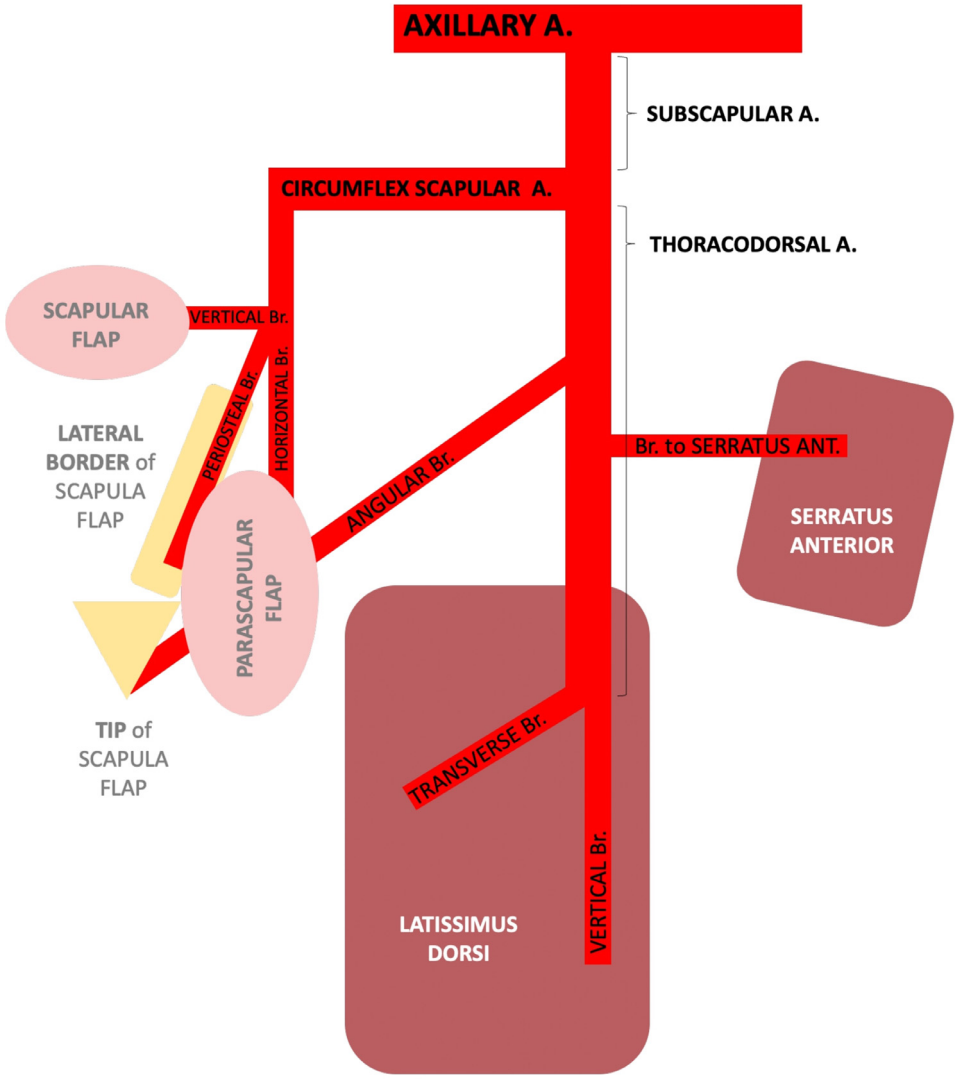

Figure 3. Thoracodorsal pedicle configuration.

plateau should be taken into consideration when evaluating this modern and minimally invasive surgical approach.[20]

2. Pedicle configuration

According to the Mathes and Nahai classification, the LD is a type V muscle with a dominant artery (thoracodorsal) and secondary segmental vessels from lumbar (medial paraspinal) and posterior intercostal (lateral) perforators.[26] Its main pedicle, the thoracodorsal artery, is a branch of the subscapular system and enters the muscle 8–12 cm proximal to its humeral insertion.

The anatomical configuration of the pedicle (Figure 3), which is very consistent, contributes to the versatility of the flap: a wide range of configurations can be achieved, making it suitable for nearly any recipient site scenario.

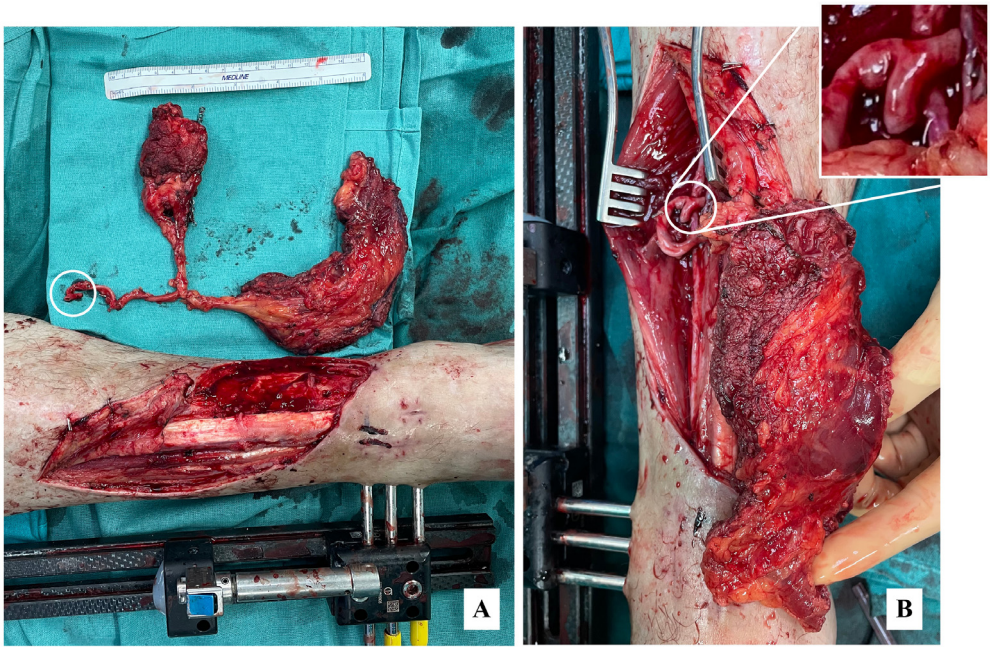

Figure 4. Demonstration of the use of a chimeric latissimus dorsi – scapular tip flap with "T" pedicle configuration to treat a chronic tibia osteomyelitis. The absence of adequate recipient vessels due to lower limb atherosclerosis led to the need for an angioplasty prior to reconstruction. During surgery, a healthy segment of anterior tibial artery (ATa) was chosen for the anastomosis. A double termino-terminal (T-T) anastomosis between subscapularis - ATa plus ATa - circumflex scapularis was performed, therefore avoiding a termino-lateral anastomosis in a sclerosed vessel or, what would have been worse, an only termino-terminal anastomosis to the ATa and the loss of one vascular axis to the foot. (A) Shows the chimeric flap composition and pedicle "T" configuration. (B) Demonstrates the insetting of the flap and preparation of the pedicle for double T-T anastomosis. This case belongs to Dr. Ruiz-Cases.

Because the artery divides into two branches (medial and lateral) in the substance of the muscle (parallel to its superior and anterior edge), it can be split longitudinally to form a bilobed or two tongued flap.[27] This is only the first of many variations attributable to the flap's pedicle conformation.

The flap can be also based on its segmental pedicles, arising from the posterior intercostal and lumbar arteries. These segmental pedicles are arranged into medial and lateral rows, 5–10 cm from the posterior midline. Flaps based on this segmental blood supply are useful for posterior trunk reconstruction.[28]

Other flap variants that can be accredited to the anatomy of its pedicle is the possibility of taking another branch of the system (circumflex scapular o branch to serratus anterior, for instance) together with the thoracodorsal artery and further dissect the pedicle until reaching the subscapular artery, therefore building a "T" conformation, so that two termino-terminal anastomoses can be performed. This allows for the preservation of the vascular axis at the recipient site, which is many times convenient, especially when talking about the lower extremity (Figure 4).

Furthermore, the fact that all these tissues (Figure 3) are supplied by the same axis (subscapular artery) in a very constant manner makes it possible to build numerous flap variants, composed by one or another combination of flaps in the form of "chimeras." The reconstructive surgeon will be able to "play" and ultimately compose a unique flap, specifically tailored to fit a given defect.

An additional advantage of the thoracodorsal/subscapular axis lies in the quality and range of vessel calibers it offers, enabling surgeons to select appropriate diameters for microvascular anasto-

moses and thereby minimize mismatch-related complications. This feature is particularly valuable when planning free tissue transfer in complex reconstructions.

3. Flap composition
   As a consequence of the above-mentioned pedicle configuration, the flap might be harvested with nearly any type of tissue found in the human body, including bone (scapula or rib), muscle (latissimus, serratus anterior), skin (island over latissimus dorsi or over the scapula – scapular or parascapular flaps) and its underlying adipose tissue.
   Supplied by the thoracodorsal and/or subscapular systems, this region effectively serves as a "tissue bank," offering countless possible combinations that can be tailored to virtually any reconstructive scenario. The flap can therefore be designed as muscle-only, myocutaneous, bilobed, osteomyocutaneous (rib or scapula), or as part of a subscapular system chimeric flap.[29]
   Among these options, splitting techniques deserve particular emphasis. Partial harvest of the latissimus dorsi permits preservation of a significant portion of the muscle together with its motor nerve supply, thereby maintaining shoulder function and reducing donor-site morbidity. In addition, when harvested with its motor nerve, the transferred segment can be reinnervated at the recipient site, allowing functional reconstruction in selected cases.
   With regard to the osseous component, the scapula or rib can be harvested in combination with the flap. While highly suitable for reconstruction of the upper two-thirds of the face (commonly employed in maxillary defects),[30–33] these bone segments are generally less optimal than the free fibula flap (FFF) for mandibular or lower limb reconstruction, particularly when load-bearing capacity is required. Nevertheless, even in such situations—and acknowledging that the FFF remains the gold standard—the scapular free border or scapular tip provide reliable bone healing while simultaneously offering additional tissue components (muscle or skin) when needed (Figure 5). Importantly, in elderly patients, scapular or subscapular-based flaps combined with the latissimus dorsi may present a distinct advantage, as vessel quality in this axis is often superior to that of the fibula, which may be compromised by age-related vascular changes.
4. Modality
   The latissimus dorsi muscle is highly suitable for both local use and as a free flap, serving purposes such as defect coverage and/or functional restoration, with or without re-innervation. This is primarily attributable to several key anatomical characteristics. Its large volume makes it particularly effective for covering extensive defects and filling voids, it being the largest muscle in the human body by surface area. Furthermore, the muscle's consistent vascular supply ensures ease of harvesting and transfer as a free flap for micro-anastomosis. Finally, its wide arc of rotation facilitates transposition to various regional sites, including the chest, back, and neck.
   An organized classification of all the different uses for which this flap has been reported in the published literature can be found further within this text (Tables 1 and 2).

Other advantages

Added to the previously mentioned advantages, there are various other positive aspects to our S.W.A.T. flap:

- Ease in dissection:

The latissimus dorsi is arguably one of the easiest flaps to elevate in the reconstructive armamentarium of any plastic surgeon. Its constant anatomy, especially regarding pedicle configuration, makes its harvest a highly predictable procedure, and therefore fairly straight-forward.

It is reported in various of our specialty's surgical manuals as being rapid, easy and safe.[34] For instance, in his chapter "Considerations in Flap Selection" in Wei and Mardini's "Flaps and Reconstructive Surgery," professor G. G. Hallock considers the LD as an "easy" flap to dissect. To note, only twelve other flaps amongst the thirty-eight analyzed are assigned to this category, three of which (scapular, parascapular and TDAP – thoracodorsal artery perforator) share the same vascular axis as the latissimus dorsi.[34]

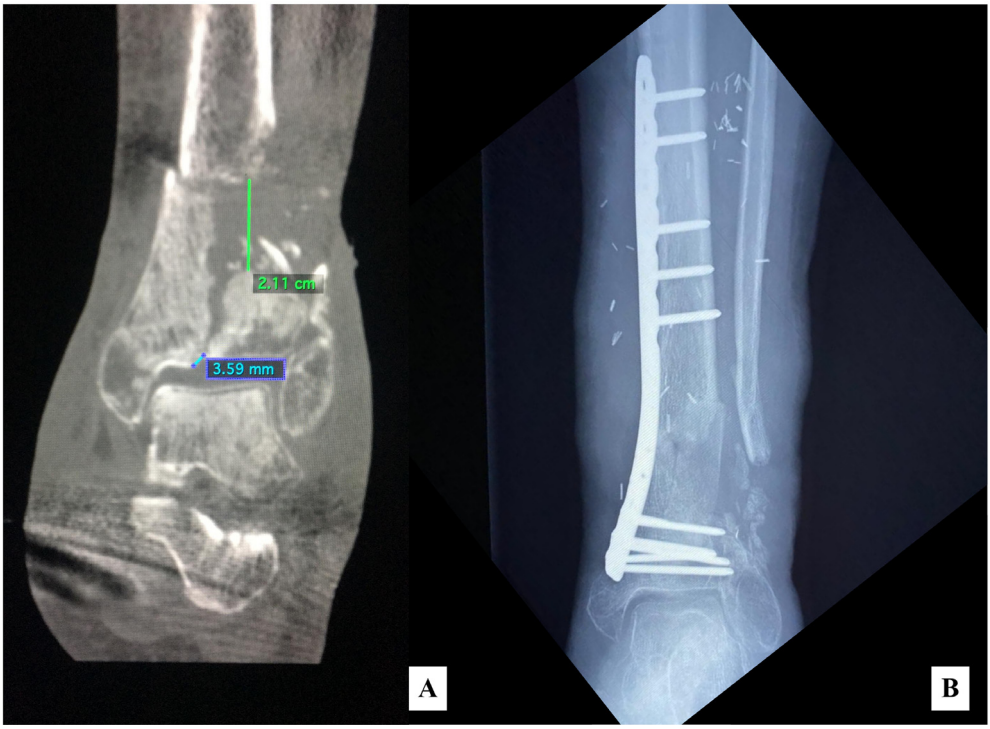

Figure 5. Demonstration of the use of a chimeric latissimus dorsi – scapular tip flap for bone reconstruction in the scenario of a chronic tibia osteomyelitis. (A) CT scan depicting the size of the bone defect and the height of the preservable articular surface. (B) Postoperative X-ray showing stable bone consolidation. This case belongs to Dr. Thione and Dr. Landín.

- Space for the unexpected:

Reconstructive surgeons often collaborate with other specialties, each with its own quirks and twists. Operating rooms are usually crowded, and surgeries tend to be long. This gives place to a non-negligible risk of last-minute changes. What was a minor defect an hour ago might have grown into something bigger. What was living before might now show signs of suffering. New enemies may surprise us on the battlefield at any moment, most often unexpectedly. We have all sometimes struggled in those situations.

Experience tells us we should keep at least one lifeboat and "not take any tissue for granted." In this sense, the latissimus dorsi flap offers many options. If fully elevated, its size is usually enough for coverage of relatively significant defects and the increase in size they may undergo during surgery. Also, when elevated with a skin island, the latter can be individualized and rotated in a propeller-style (razor flap)[35] for coverage of additional areas that were initially unexpected. For this reason, we recommend always taking a skin island with the flap. Direct donor-site closure can be achieved even with big skin islands, so there is no good reason not to take one "just in case." The advantages of elevating the flap in a musculocutaneous configuration outweigh its disadvantages.

Some weaknesses

Harvest of this muscle causes shoulder weakness and girdle instability which, while not affecting activities of daily living in most patients, can produce notable deficits in patients who rely on walkers, wheelchairs, or crutches for mobility. Therefore, while this flap is an attractive option in many other parts of the body, the functional loss of the latissimus dorsi must be considered in lower extremity

Table 1
Free latissimus dorsi flap.

Location	Coverage	Functional non-innervated	Functional innervated
Head and neck	Coverage after tumor resection,[31,39–54] infection,[55,56] trauma,[57–59] or osteonecrosis.[60]	Pharyngeal reconstruction following oncologic resection[61] and functional lower lip reconstruction following trauma or tumor.[62]	Reconstruction of floor of mouth following oncologic resection[63] and cervicofacial reconstruction following tumor resection,[64–69] infection[70] or exeresis of giant arterio-venous malformation.[71]
Thorax and back	Coverage of lumbosacral region[72,73] or chest-wall[74] following tumor resection.	Coverage of aortic prosthesis following infection.[75]	–
Breast	Breast reconstruction.[76]		–
Upper limb	Elbow reconstruction following tumor resection[77] or finger coverage after trauma or infection.[78]	–	Triceps reconstruction following tumor resection,[79] reconstruction of flexor and extensor compartments following Volkmann's contracture[80] and Targeted Muscle Reinnervation (TMR) in trans-humeral amputation.[81]
Abdomen and pelvis	Abdominal wall reconstruction following tumor resection[82,83] or entero-cutaneous fistula.	Abdominal wall reconstruction following tumor resection.[74,84]	Neo-phalloplasty[85–87] and detrusor reinnervation following low neuronal lesion.[88]
Lower limb	Defect coverage following trauma (for traumatic amputations,[89] knee defects,[90,91] ankle defects,[92,93] tibia open fractures[94] or complex multifocal defects[95–98]), tumor resection,[73,94,99] infected hip arthroplasty,[100] knee arthroplasty,[101,102] chronic ischemia (Lisfranc amputation)[103] or burns.[104]	Functional foot reconstruction following trauma[105] or chronic osteomyelitis[106], knee arthroplasty coverage[102] and coverage of hemipelvectomy stump following tumor resection.[107]	Anterior (extensor) compartment[108] and posterior (flexor) compartments[109] reconstruction after traumatic amputations.

reconstructions, where many of these patients will be crutch or wheelchair-dependent for a prolonged amount of time.[28]

Also, there is a notable risk of seromas, which can be reduced with quilting sutures and drains.[28,33,34]

Literature review

To support our thesis, we conducted a systematic review in accordance with the Preferred Reporting Items for Systematic Reviews and Meta-Analyses (PRISMA)[35] guidelines (Supplementary Material 1 and 2) on the published uses of the latissimus dorsi flap in reconstructive surgery, searching for evidence to sustain our theory that what we call the "S.W.A.T. flap" really deserves consideration as such a distinguishable weapon in our arsenal.

One electronic database (*Medline*) was queried from June 4, 2024 to July 30, 2024 using the following research strategy:

- *Medline*: ((lat flap [Title]) OR (latissimus dorsi flap [Title])) OR (latissimus flap [Title]).

From inception to July 2024, all resulting articles were compiled, and duplicate titles were removed. Two reviewers screened the remaining titles and abstracts, collecting all articles meeting our

Table 2
Pedicled Latissimus dorsi flap.

Location	Coverage	Functional non-innervated	Functional innervated
Head and neck	Coverage after tumor resection[110,111] or burn.[112]	–	–
Thorax and back	Coverage after tumor resection,[113–121] tissue necrosis (secondary to extravasation,[122,123] radionecrosis,[124,125] pressure sore[126] or wound border necrosis[127,128]) or gunshot trauma.[129]	Repair of congenital diaphragmatic hernia or post-oncologic defects,[130–134] closure of bronchopleural fistulae,[135,136] repair of esophageal perforation[137] and chest reconstruction in Poland and Jarcho-Levin syndromes.[138,139]	Diaphragm reinnervation after congenital diaphragmatic hernia[140] and recovery of shoulder elevation after oncologic trapezius muscle resection.[141]
Breast	Breast reconstruction.[24,25,142–176]		–
Upper limb	Coverage after traumatic defect (elbow and arm),[81,177,178] burn (trans-humeral amputation),[179] axillary hidradenitis,[180,181] tumor resection (arm and shoulder)[182] or infection (shoulder) .[183] 05/09/2025 18:32:00	Rotator cuff reconstruction,[184] functional recovery of shoulder and upper limb mobility following tumor or trauma[185–193] and upper-limb lymphedema or axillary lymphorrhea treatment after breast cancer.[143,194] 05/09/2025 18:32:00	
Abdomen and pelvis	Coverage after trauma.[195]	–	–
Lower limb	–	–	–

inclusion criteria: articles published in English, Spanish or French (languages spoken by both reviewers), with full-text freely available or retrievable via our institution's library (Hospital La Fe), published in indexed journals, on common and original indications of the latissimus dorsi flap in reconstructive surgery.

We excluded publications in conferences or congresses, letters to the editor, press releases, editorials, comments, reviews and cohort studies. In such way, only case-series were collected, as the purpose of our study was to compile only the reported indications the flap had been used for and not comparing or contrasting it with other reconstructive methods.

Both reviewers independently revised the selected articles, individually extracting the relevant data, which was later combined and contrasted. The following data was collected: author, defect location and indication, flap type (pedicled or free), recipient vessels and presence or absence of reinnervation. No protocol was prepared or registered for this systematic review.

Our search yielded 450 publications via *Medline* and 36 articles retrieved through citation searching. Initial screening reduced the sample to 415 publications. After reading all titles and abstracts and applying our exclusion criteria, only 249 articles were selected. Finally, following full-text reading, a total 161 articles were included in our review.

As the purpose of our review was just descriptive, we did not perform any statistical analysis, but only compiled and arranged the published indications of the latissimus dorsi for the reader to appreciate its notable versatility. Tables 1 and 2 synthesize all the described uses for this flap according to their location, which have been grouped into 5 areas: head and neck, thorax and back, upper limb, abdomen and pelvis and lower limb. A specific section was attributed to the breast inside "thorax and back," in the light of its importance in terms of numbers, probably being the most frequently used indication for this flap. Flaps are classified as to whether they were used only for coverage or for a functional restoration, be this innervated or non-innervated. References for these tables can be found as Supplementary Material 3.

Conclusion

The latissimus dorsi flap, with its exceptional versatility and adaptability, stands as a cornerstone in reconstructive surgery. Its wide range of applications, from simple coverage to complex functional restoration, makes it an invaluable tool for surgeons facing challenging defects. The consistency in its anatomical configuration, multiple harvesting techniques, and potential for chimeric flaps further enhance its utility.

This systematic review evidences the LD flap's extensive use across various anatomical regions and reconstructive scenarios reinforces its recognition as the "S.W.A.T. flap," an indispensable resource in the reconstructive surgeon's armamentarium.

Funding

The authors acknowledge the Department of Anatomy and Embryology of the University of Valencia for covering the article processing charges. No funding was received for the research or authorship.

Ethical approval

Not required.

Declaration of competing interest

None declared.

Supplementary materials

Supplementary material associated with this article can be found, in the online version, at doi:10.1016/j.jpra.2025.08.037.

References

1. Tactical Response and Operations Standard for Law Enforcement Agencies. 2015.https://ntoacommandcollege.org/wp-content/uploads/2016/03/NTOA-Tactical-Response-and-Operations-Standard-2015-FINAL.pdf
2. Bostwick J. Latissimus dorsi flap - current applications. *Ann Plast Surg.* 1982;9(5):377–380.
3. Tansini: nuovo processo per amputations della mammella... - Google Scholar. Accessed July 10, 2024. https://scholar.google.com/scholar_lookup?hl=en&volume=12&publication_year=1896&pages=3&journal=Riforma+Medica&author=I+Tansini&title=Nuovo+processo+per+l%27amputazione+della+mammaella+per+cancre.
4. Tansini: sopra il mio nuovo processo di amputazione... - Google Scholar. Accessed July 10, 2024. https://scholar.google.com/scholar_lookup?hl=en&volume=57&publication_year=1906&pages=141&journal=Gazz+Med+Ital&author=I+Tansini&title=Spra+il+mio+nuovo+processo+di+amputazione+della+mammaella.
5. Tansini I. *ScrittiMedici*. Milano, Italy: Wassermann; 1935.
6. Olivari N. The latissimus flap. *Br J Plast Surg.* 1976;29(2):126–128. doi:10.1016/0007-1226(76)90036-9.
7. Quillen CG, Shearin JC, Georgiade NG. Use of the latissimus dorsi myocutaneous island flap for reconstruction in the head and neck area: case report. *Plast Reconstr Surg.* 1978;62(1):113–117. doi:10.1097/00006534-197807000-00028.
8. Maxwell GP, Stueber K, Hoopes JE. A free latissimus dorsi myocutaneous flap. *Plast Reconstr Surg.* 1978;62(3):462.
9. May JW, Lukash FN, Gallico GG. Latissimus dorsi free muscle flap in lower-extremity reconstruction. *Plast Reconstr Surg.* 1981;68(4):603–607. doi:10.1097/00006534-198110000-00022.
10. Bailey B.N., Godfrey M. Latissimus dorsi muscle free flaps. *Br J Plast Surg.*
11. Farid M, Nikkhah D, Rawlins J. Thoracodorsal artery flap: latissimus dorsi flap. In: Nikkhah D, Rawlins J, Pafitanis G, eds. *Core techniques in flap reconstructive microsurgery: a stepwise guide.* Heidelberg, Germany: Springer International Publishing; 2023:133–151. doi:10.1007/978-3-031-07678-7_14.
12. Wolff KD, Hölzle F. *Raising of microvascular flaps. A systematic approach.* Heidelberg, Germany: Springer International Publishing; 2005.
13. Shuck JW, Felder JA, Shammas RL, Chang EI, Selber JC, Phillips BT. Down with the bean bag: a multi-institutional experience with total latissimus muscle free flap harvest in the supine position. *Plast Reconstr Surg Glob Open.* 2023;11(1):e4755. doi:10.1097/GOX.0000000000004755.
14. Kim DG, Kim JS, Lee JS, Lee J, Park HY, Yang JD. The usefulness of endoscopic harvesting of the latissimus dorsi flap for breast reconstruction using a single-port and CO2 gas insufflation technique. *Aesthetic Plast Surg.* 2021;45(6):2681–2690. doi:10.1007/s00266-021-02467-1.
15. Pomel C, Missana MC, Atallah D, Lasser P. Endoscopic muscular latissimus dorsi flap harvesting for immediate breast reconstruction after skin sparing mastectomy. *Eur J Surg Oncol.* 2003;29(2):127–131. doi:10.1053/ejso.2002.1326.

16. Missana MC, Pomel C. Endoscopic latissimus dorsi flap harvesting. *Am J Surg*. 2007;194(2):164–169. doi:10.1016/j.amjsurg.2006.10.029.
17. Cho BC, Lee JH, Ramasastry SS, Baik BS. Free latissimus dorsi muscle transfer using an endoscopic technique. *Ann Plast Surg*. 1997;38(6):586–593. doi:10.1097/00000637-199706000-00004.
18. Lin CH, Wei FC, Levin LS, MC Chen. Donor-site morbidity comparison between endoscopically assisted and traditional harvest of free latissimus dorsi muscle flap. *Plast Reconstr Surg*. 1999;104(4):1070–1077 quiz 1078.
19. Cha W, Jeong WJ, Ahn SH. Latissimus dorsi muscle free flap revisited: a novel endoscope-assisted approach. *Laryngoscope*. 2013;123(3):613–617. doi:10.1002/lary.23757.
20. Vourtsis SA, Paspala A, Lykoudis PM, et al. Robotic-assisted harvest of latissimus dorsi muscle flap for breast reconstruction: review of the literature. *J Robot Surg*. 2022;16(1):15–19. doi:10.1007/s11701-021-01232-5.
21. Selber JC, Baumann DP, Holsinger FC. Robotic latissimus dorsi muscle harvest: a case series. *Plast Reconstr Surg*. 2012;129(6):1305. doi:10.1097/PRS.0b013e31824ecc0b.
22. Clemens MW, Kronowitz S, Selber JC. Robotic-assisted latissimus dorsi harvest in delayed-immediate breast reconstruction. *Semin Plast Surg*. 2014;28(1):20–25. doi:10.1055/s-0034-1368163.
23. Chung JH, You HJ, Kim HS, Lee BI, Park SH, Yoon ES. A novel technique for robot assisted latissimus dorsi flap harvest. *J Plast Reconstr Aesthet Surg*. 2015;68(7):966–972. doi:10.1016/j.bjps.2015.03.021.
24. Pu L, Karp N. *Atlas of reconstructive breast surgery*. 1st ed. Chapter 8: Latissimus Dorsi Flap Breast Reconstruction; 2019.
25. Bleicher JN, Garred J. Bilobed latissimus dorsi flap for a decubitus ulcer. *Plast Reconstr Surg*. 1984;73(3):459–461. doi:10.1097/00006534-198403000-00024.
26. Neligan PC *Plastic surgery*. 4. 5th ed. Amsterdam, Netherlands: Elsevier; 2023.
27. Rethman B, Al Azri SAD, Melville JC, Huang A, Shum JW. Practical tips for harvesting Latissimus dorsi free flap. In: Amin D, Marwan H, eds. *Pearls and pitfalls in oral and maxillofacial surgery* Springer International Publishing; 2024:261–266. doi:10.1007/978-3-031-47307-4_37.
28. Clark JR, Vesely M, Gilbert R. Scapular angle osteomyogenous flap in postmaxillectomy reconstruction: defect, reconstruction, shoulder function, and harvest technique. *Head Neck*. 2008;30(1):10–20. doi:10.1002/hed.20649.
29. Ferrari S, Ferri A, Bianchi B. Scapular tip free flap in head and neck reconstruction. *Curr Opin Otolaryngol Head Neck Surg*. 2015;23(2):115–120. doi:10.1097/MOO.0000000000000137.
30. Tang AL, Bearelly S, Mannion K. The expanding role of scapular free-flaps. *Curr Opin Otolaryngol Head Neck Surg*. 2017;25(5):411–415. doi:10.1097/MOO.0000000000000393.
31. Wei FC, Mardini S. *Flaps and Reconstructive Surgery*. Netherlands: Elsevier.Amsterdam. 2nd ed.
32. Cavadas PC, Teran-Saavedra PP. Combined latissimus dorsi-thoracodorsal artery perforator free flap: the “razor flap. *J Reconstr Microsurg*. 2002;18(1):29–31. doi:10.1055/s-2002-19706.
33. Sajid MS, Betal D, Akhter N, Rapisarda IF, Bonomi R. Prevention of postoperative seroma-related morbidity by quilting of latissimus dorsi flap donor site: a systematic review. *Clin Breast Cancer*. 2011;11(6):357–363. doi:10.1016/j.clbc.2011.04.006.
34. Ismaïl M, Boucher F, Chauvel-Picard J, Shipkov H, Braye F, Mojallal A. Séquelles du prélèvement du lambeau de grand dorsal et ses dérivés – Revue de la littérature. *Ann Chir Plast Esthet*. 2014;59(5):348–354. doi:10.1016/j.anplas.2014.05.002.
35. Shea BJ, Reeves BC, Wells G, et al. AMSTAR 2: a critical appraisal tool for systematic reviews that include randomised or non-randomised studies of healthcare interventions, or both. *BMJ*. 2017;358:j4008. doi:10.1136/bmj.j4008.