Journal of Pediatric Surgery Open 8 (2024) 100163

Contents lists available at ScienceDirect

Journal of Pediatric Surgery Open

journal homepage: www.elsevier.com/locate/yjpso

Airway exploration when suspected foreign body aspiration. Is it always indicated?☆

Maria Martinez Diaz *, Vicente Ibañez Pradas, Miguel Couselo Jerez, Estíbaliz Valdés Diéguez

Hospital Universitari i Politècnic La Fe. Avinguda de Fernando Abril Martorell, n° 106. 46026 Valencia (Spain), Carrer Del Progrés 83, 46011 València, Valencia, España

ARTICLE INFO

Keywords:
Foreign body aspiration
Bronchoscopy
Children

ABSTRACT

Background: Foreign body aspiration (FBA) is an important cause of morbidity and mortality in pediatrics. Flexible or rigid bronchoscopy is the gold standard for its diagnosis and treatment. However, despite being a minimally invasive test, it is not without risk and, given the low specificity of symptoms involved, between 45 and 70 % of diagnostic bronchoscopies (DB) performed are normal. The aim of this paper is to develop a strategy in order to reduce this percentage.

Methods: Observational, analytical, and retrospective study of DB performed for suspected FBA between 2018 and 2022. Demographic, clinical, and radiological data, bronchoscopy findings and complications were obtained.

Results: 96 patients admitted to DB were analyzed. 72 out of 96 (75 %) were normal. The risk of presenting a foreign body was significantly higher in patients with suspected nuts, so DB should be always indicated. In patients with suspected other materials aspiration, a multivariate analysis was performed using logistic regression. Statistically significant association was found between dyspnea, asymmetric auscultation and abnormal chest radiography with the presence of a foreign body on the DB; AUC = 0.97 (95 % CI 92.4 %-100 %). The proposed algorithm establishes patients at high risk of FBA and therefore the DB is recommended, with a sensitivity of 100 % and a specificity of 87.2 %.

Conclusions: The application of the algorithm to patients with suspected aspiration of a foreign body other than nuts can facilitate the identification of patients with high risk of aspiration and reduce the percentage of negative DB.

Abbreviations

AE	Airway exploration
CT	Computed tomography scan
FBA	Foreign body aspiration
FB	Foreign body
ICU	Intensive care unit
OTI	Orotracheal intubation

Introduction

Foreign body aspiration (FBA) is a potential life-threatening problem, especially in children under the age of five [1-4]. Although mortality rate has decreased until 0,9 %, it is the leading cause of accidental death during the first year of life and the third one in children under four [5,6]. The most frequent type of foreign body is organic, specially seeds and nuts [2,6-8].

The presence of a foreign body (FB) in the airway causes a partial or complete obstruction of the same, resulting in diverse symptoms depending on the degree and location of the obstruction. The triad of choking, wheezing, and unilateral hypoventilation is highly suggestive of aspiration, but it is only present in 15–25 %. Therefore, clinical presentation will be nonspecific most of times [7]. In addition, 20 % of cases are not witnessed, and physical examination or chest X-rays will be without specific changes in 36,7 % and 47,1 % respectively [6,8].

Flexible or rigid bronchoscopy are the gold standard for diagnosis and treatment [1,3,5,9], but they are also invasive procedures requiring general anesthesia and with a morbidity and mortality rates ranging from 2,9 to 9 % and from 0 to 1,5 % respectively [9]. Desaturation, laryngeal edema, pneumonia or broncholaryngospasm have been

☆ Level of Evidence: II

* Corresponding author.
E-mail addresses: mariamartinezdiaz115@gmail.com, mmartdiaz95@gmail.com (M. Martinez Diaz).

https://doi.org/10.1016/j.yjpso.2024.100163
Received 25 April 2024; Received in revised form 14 July 2024; Accepted 14 July 2024
Available online 27 July 2024
2949-7116/© 2024 The Author(s). Published by Elsevier Inc. This is an open access article under the CC BY-NC license (http://creativecommons.org/licenses/by-nc/4.0/).

reported, especially in patients misdiagnosed and with concurrent respiratory symptoms, in which bronchoscopy can worsen their airway disease [9,10].

Given the heterogeneity of clinical presentation, lack of specific signs and symptoms, and the risk associated to missed FB, the threshold to perform a diagnostic bronchoscopy (DB) is low, and, as a consequence, a high rate of negative explorations is usually reported [9,10]. Taking into account that AE is not an innocuous procedure, it is important to identify patients at low risk of FBA in order to avoid unnecessary explorations. Several studies have proposed predictive models to improve diagnostic accuracy in children with suspected FBA but, for the moment, there are no determined criteria to indicate AE, especially in mild symptomatic or asymptomatic patients [2,5].

The aim of this study is to identify patients at low risk of FBA and to develop an algorithm to support clinical decision-making.

Methods

Observational, analytical, and retrospective study was conducted in La Fe Children's Hospital from January 2018 to December 2022.

Subjects aged less than 15 years old who underwent diagnostico bronchoscopy (rigid or flexible) for suspected FBA between 2018 and 2022 in Pediatric Surgery Department of La Fe Children's Hospital were enrolled. We excluded patients consulting in Pediatric Emergencies because of witnessed gagging but not undergone to bronchoscopy. Bronchoscopies performed for a different reason other than suspected aspiration were also excluded.

Patient demographics (age and sex), clinical presentation, physical findings and chest X-ray results were collected, as well as foreign body's nature and complications in accordance to the Clavien-Dindo classification. The clinical charts recorded were witnessed gagging, *peri* oral cyanosis, dyspnea/tachypnea, cough, fever, stridor or wheezing reported by relatives. We consider dyspnea/tachypnea as difficulty to breath after the choking episode referred by the witnesses. Physical examination findings recorded were unilateral hypophonesis, rhonchus or wheezing, but after analyze the results we summarized them in asymmetric auscultation. Chest X-ray results were categorized as: hyperinflation, consolidation, atelectasis, radio-opaque foreign body and without findings. Several types of foreign bodies were described, and four categories were differentiate: seeds or nuts, inorganic, other organic (different from nuts) and unspecified.

DB was performed under sedation-anesthesia conditions. Flexible bronchoscopy was indicated as diagnostic procedure and only when FBA was verified, rigid bronchoscopy was performed to help in its removal. In patients who underwent only flexible bronchoscopy, the most widely used procedure was sedation with sevoflurane, spontaneous ventilation and cardiorespiratory monitoring.

Descriptive analysis of the aforementioned variables was performed. Continuos variables were expressed by their mean and standard derivation values, and categorical ones by their absolute and relative values. T-test or Mann-Withney *U test* were used for comparison between continuous variables depending on their adjustment to normal distribution. Chi square test or Fisher's test were used for comparison between categorical ones. A p value $< 0,05$ was consider statistically significant. Multivariable analysis was conducted through a logistic regression model. Variables with a p-value $< 0,10$ in univariate anaylisis were considered for inclusion in the multivariate model. The diagnostic performance of the regression model was determined by its ROC curve. IBM SPSS Statistics 29.0.2.0 was used for the statistical analysis.

In order to stablish a clinical decision model, we considered Pauker and Kasirer's concept on therapy threshold [11-13], which states that clinicians should stablish, for any medical condition, a probability from which therapy would be the right decision, while adding new diagnostic test would not modify the course of action. For our purpose, and given the risk associated to a missed FB, we will consider 50 % as our threshold to perform DB.

Results

During the study period 96 DB-FBA were performed. Patients were mainly male (59 cases; 61,5 %) with a mean age of 33 ± 3.35 months and a range between 4 and 120 months (Table 1).

The most frequent anamnesis data were witnessed gagging in 66 patients (68,8 %), cough in 59 (61.5 %), and dyspnea in 40 (41.7 %). In 18 patients (18.8 %) perioral cyanosis during the choking episode was described. Stridor and wheezing was reported by family members in 13 (13,5 %) and 8 (8.3 %) cases respectively. The type of foreign body related with the aspiration episode was most frequently nuts (n=34; 35.4 %), followed by organic (n=30; 31.2 %) and inorganic (n=25; 26 %). In 7 patients (7.3 %) the type of foreign body was not specified. Physical examination revealed unilateral hypophonesis in 25 patients (26 %) and unilateral rhonchus or wheezing in 12 (12.5 %). A chest X-ray was performed in 88 patients (91.8 %) and resulted without remarkable findings in 59 (61.5 %). For those with altered X-ray, 13 (13.5 %) showed hyperinflation, 12 (12.5 %) consolidation, and 4 (4.2 %) atelectasis (Table 1).

75 % of DB were negative for FB ($n = 72$). Among 24 positive DB, the location of FB was bronchial in 83,3 % ($n = 20$) and tracheal in 16,7 % ($n = 4$). Orotracheal intubation was required in 55,2 % of the sample during de intervention. The FB was successfully removed at first attempt in 79,1 % ($n = 19$), whereas in five cases the extraction technique failed due to edema and mucosal bleeding, requiring a second attempt to complete the procedure. Complications were registered in two patients (2,08 %), both of them without FB and classified as Clavien-Dindo II (bronchospasm solved with adrenaline nebulization and oxygen therapy), and IVa (bronchospasm requiring OTI and ICU admission). As routine practice in our center, after FB extraction all patients were admitted to the ICU for monitoring, in addition to 5 patients with negative AE who were admitted because of respiratory events during

Table 1
Demographic characteristic of patients with airway exploration (AE) performed for suspected FBA. Univariant analysis.

Variable	Total ($N = 96$) n (%)	DB + $n = 24$ (%)	DB – ($n = 72$)	p-value
Sex				
• Male	59 (61,45)	13 (54,17)	46 (63,89)	0,397
• Female	37 (38,54)	11 (45,83)	26 (36,11)	
Anamnesis				
• Witnessed chocking	66 (68,75)	18 (75,00)	48 (66,67)	0,446
• Cyanosis	18 (18,75)	5 (20,83)	13 (18,06)	0,487
• Dyspnea	40 (41,66)	15 (62,50)	25 (34,72)	**0,017**
• Cough	59 (61,46)	17 (70,83)	42 (58,33)	0,276
• Stridor	13 (13,54)	4 (16,67)	9 (12,50)	0,416
• Wheezing	8 (8,33)	2 (8,33)	6 (8,33)	0,682
Physical examination				
• Unilateral hypophonesis	25 (26,04)	15 (62,50)	10 (13,89)	**<0,001**
• Rhonchus/ Wheezing	12 (12,50)	7 (29,16)	5 (6,94)	**0,009**
Chest X-ray				
• Normal	59 (61,46)			
• Pathologic	29 (30,21)	16 (66,67)	14 (19,44)	**<0,001**
◦ Air trapping	13 (13,54)			
◦ Consolidation	12 (12,50)			
◦ Atelectasis	4 (4,17)			
Tipe of foreign body				**0,009**
• Nuts/Seeds	34 (35,41)	15 (62,50)	19 (26,39)	
• Organic	30 (31,25)	6 (25,00)	24 (33,33)	
• Inorganic	25 (26,04)	3 (12,50)	22 (30,56)	
• Unknown	7 (7,29)	0 (0,00)	7 (9,72)	

emergence from anesthesia.

Comparisons between groups revealed differences in dyspnea/tachypnea was statistically significantly related to the presence of a FB ($p = 0.017$) while the other anamnesis variables showed no differences. The type of FB was significantly related to the probability of aspiration ($p = 0.009$) so that 62.5 % of positive DB were due to nuts or seeds. On the other hand, suspected organic material aspiration led on 80 % of negative DB, inorganic on 88 % and when the material was unspecified 100 % were negatives (Fig. 1). None of the foreign bodies were radio-opaque so there were not detected on X-ray. Both abnormal physical findings (unilateral hypophonesis or rhonchi and/or unilateral wheezing) and altered chest X-ray were associated with the presence of a foreign body ($p < 0.001$; $p = 0.009$; $p < 0.001$ respectively) (Table 1).

With this background we stablished our clinical scenario. We considered that patients with chocking episodes involving nuts ($n = 34$) should go directly to DB, given their prevalence of FB, whereas the rest of the sample ($n = 62$) should be considered for multivariate analysis. Other variables involved showed similar figures for FB (as altered X ray, or dyspnea/tachypnea) but those were considered more suitable to bias. Dyspnea/tachypnea during the aspiration episode a is subjective symptom referred by parents and difficult to corroborate and abnormal physical findings is dependent observer. Instead, the type of FB is the only objective fact related with bronchoscopy findings. Patients with suspected FBA from material other than nuts, whose pre-test probability of disease is bellow the test-treatment threshold, would benefit of performing further test and withholding AE. DB

Thereby, we obtained a sample of 62 patients, who underwent multivariate analysis using logistic regression including the four variables: dyspnea/tachypnea, unilateral hypophonesis, rhonchus or unilateral wheezing, and abnormal chest X-ray. They all shown statistic significance in multivariate analysis (Table 2). The diagnostic accuracy of the obtained logistic regression equation was assessed calculating its ROC curve. We obtained an area under the curve (AUC) of 97.2 % (95 % IC 93.3 %−100 %) and, setting the cut-off point at 0.035, the equation showed a sensitivity of 100 % and a specificity of 87, 2 % (Fig. 2).

Table 2
Multivariant analysis.

Variables	B	Sig
Dyspnea/Tachypnea	−1632	0,022
Hypophonesis	−1492	0,05
Unilateral rhonchus/wheezing	−1957	0,039
Abnormal chest X-ray	−1613	0,031
Equation= - 3308 + 1632*Dyspnea + 1492*Hypophonesis +1957*Unilateral rhonchus/wheezing + 1613*Abnormal chest X-ray		

Discussion

FBA is a frequent reason of consultation in Pediatric Emergencies, especially in children under four years, and is a potential life-threatening emergency [5,9,14-16]. The risk of FBA in this age range is attributed to the absence of posterior dentition and immaturity of the neuromuscular mechanisms for airway protection [6,8,14,17]. In our sample, the mean age is 33 months with predilection for males. It is described a higher frequency in males between 2 and 5 years old but in our case we have not found this relationship to be statistically significant, probably due to the low number of patients with positive bronchoscopy [1-6].

According with previous analyses [1,2,14,18] the most frequent clinical data were witnessed choking, cough, and dyspnea, but no patient in our sample presented the complete classic triad. Clinical findings have a sensitivity greater than 90 % and low specificity, between 24 and 59 %, and can be negative in up to 32 % of cases [3,14]. The most frequent sign is unilateral hypoventilation, present in 57 % - 78.4 % [2, 8] unlike what we observed in our sample, in which it was only described in 26 % (IC 95 % 17–35 %). Chest x-ray offer a 30–77 % specificity and specificity around 30–77 % and a sensibility between 61 and 88 % [3,14,15,18], compliant with our analysis in with we obtained 78,46 % and 68,15 % respectively.

Some predictors of FBA such as witnessed choking, unilateral decreased breath sounds, air trapping and other radiological findings suspicious of FBA have proven a strong association with positive bronchoscopy [19]. However, their value as independent predictors is insufficient. For this reason, several authors have proposed different clinical scores considering multiple variables in order to improve diagnosis accuracy [5,20-23]. Özyüksel [22] scored all the statements of anamnesis, physical examination and radiological findings of FBA, according to the sensibility and specificity of each one in previous articles. No relationship between history of aspiration and positive AE was found in this study, whereas in our serie, in agreement with others [20,21,23], clinical history was significantly related with the presence of a foreign body. On the other side, Özyüksel's results support the importance of physical examination and radiological tests [22]. Fasseeh, N. [5] developed a quantitative model to estimate the risk of FBA incorporating witnesses choking, cough, wheeze, unilateral hypoventilation or wheezing, distress, and abnormal X-ray. The score suggested, when higher than 2 predicted FBA with a sensibility and specificity of 79,9 % and 84,9 %, but 15,6 % of patients with score less than 1 had positive AE, a figure innaceptably high. In our sample, only physical examination and radiological signs agree with those findings, while dyspnea was the single clinical data related to FBA. In this line, other authors have categorised patients according to the risk of FBA, relying on the score obtained [20,23]. Depending on the punctuation, different management is proposed: rigid or flexible bronchoscopy, CT, hospital surveillance or

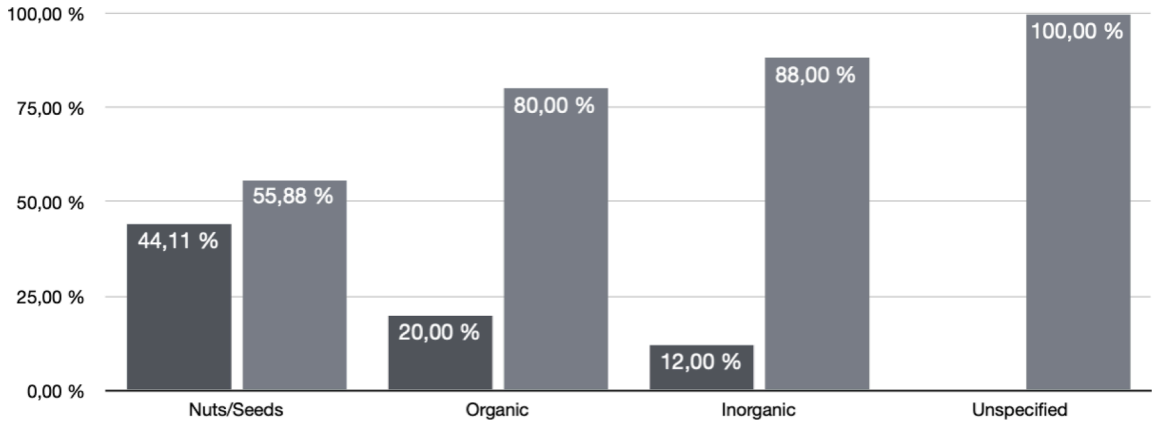

Fig. 1. Results of diagnostic bronchoscopy according to the typo of foreign body. DB +: Airway exploration with foreign body aspiration. DB - : Negative airway exploration.

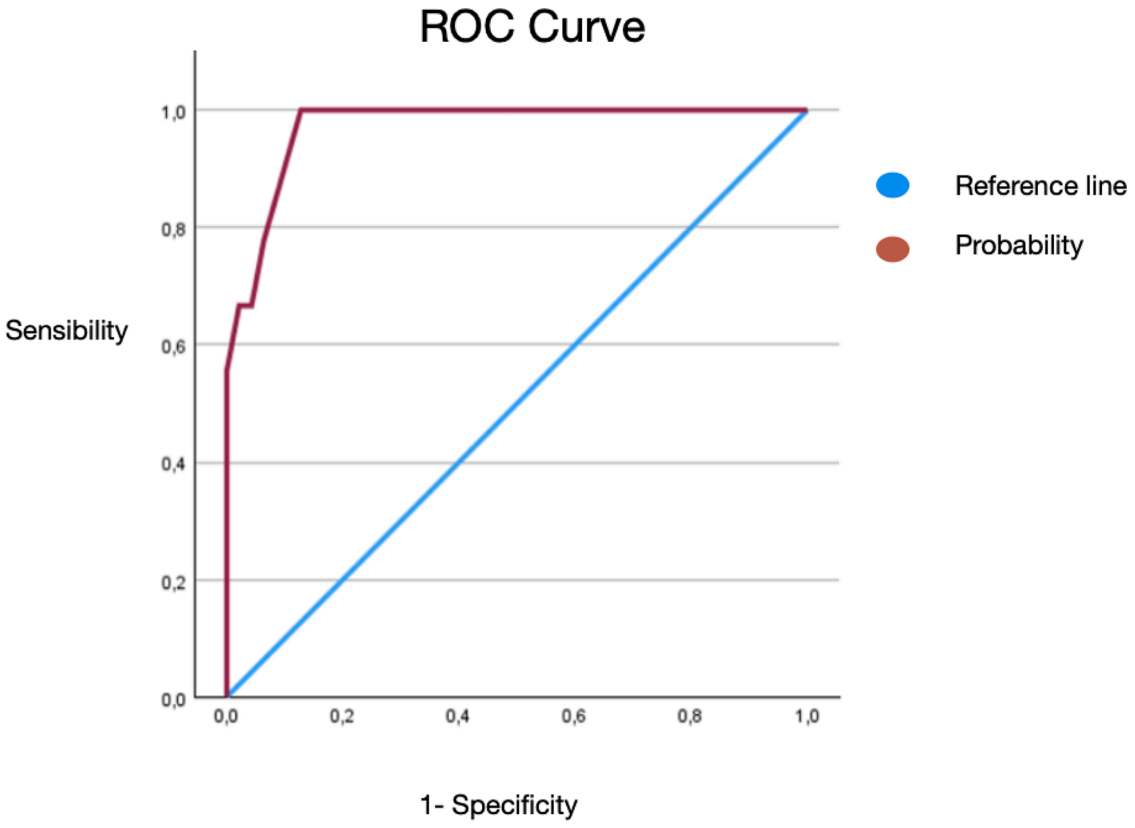

	AUC	CI 95%
Probability	0,972	0,933-1,00

Fig. 2. ROC Curve.

discharge. We tried to validate one of these scores in our hospital, but results were discouraging as 6 patients with FBA would have been missed [21]. Considering the serious consequences derived from misdiagnosis, Stafler et al. [24] focused on validating a computerized scoring system proposed by Kadmon et al. [25] which minimize false negative rates. However, the consequence of its high sensitivity was a 41 % of specificity, so that 60 % of AE performed were normal. A systematic review analyzing clinical prediction models for suspect FBA, showed high risk of bias and lack of internal and external validation [19].

Since none of the variables studied independently or in combination make it possible to predict with total certainty the presence of a foreign body in the airway, it has been proposed to perform flexible bronchoscopy in all patients with suspected FBA, as it is less invasive than rigid, causes less trauma to the airway and allows easily access to distal segments [14]. However, this strategy entails a high percentage of negative DB, which in our series is 75 % and in the literature it is between 20 and 90 % [5]. Bronchoscopy is not an innocuous procedure as it is considered an invasive technique that requires sedo-anesthesia with a rate of complications between 2 % and 17 %, such as bronchospasm, desaturation, airway trauma, vocal cord edema or bleeding [14,15,18,26]. We had a 2,08 % complication rate, both of them bronchospasm episodes in patients with negative bronchoscopy. Others have suggested the use of CT as a diagnostic complement to reduce the rate of unjustified bronchoscopies, especially in asymptomatic patients, with a sensitivity and specificity of 90–100 % and 66–100 % respectively [8,15,20,21,28]. O. G. Ahmed [28] reported a reduction of more than 50 % in negative bronchoscopies after implementing the use of chest CT in patients with intermediate risk of FBA. This practice is somewhat controversial in pediatrics due to the use of ionizing radiation. Although performing CT scans without contrast, of short duration and at a low dose (0.8–2 mSv), the risk could be compared to the risk associated to general anesthesia and manipulation of the airway [15,16,20,26,27].

Until now every published prediction model has tried to identify patients with high risk of FBA. In contrast, we aimed to select patients at low pre-test probability of aspiration to avoid unjustified DB. In our sample, foreign body material was related to the bronchoscopy findings, so that when the object was nuts or seeds, the risk of positive DB rose to 62.5 %. In concordance with the concept of diagnostic and therapeutic threshold of Pauker and Kassirer mentioned [11-13], we consider that DB is justified in these patients since the pre-test probability of disease exceeds 50 %, the sensitivity of the test is 100 % and carries an acceptable complication rate. On the other hand, the risk of positive bronchoscopy in patients with suspected aspiration of different materials as inorganic or other organics is low, so we consider it would be reasonable a different approach. This group is in our sample the most appropiate one to implement the predictive model including dyspnea/tachypnea, asymmetric auscultation and abnormal chest X-ray (Figure II). By setting the cut-off point for performing the DB at 0.3035, we obtained a sensitivity of 100 % and a specificity of 87.2 %, thus achieving a reduction in negative bronchoscopies of 42.7 %, going from 72 negative AE (75 %) to 31 (32 %). Patients with punctuation less than 0.3035 are considered at low risk of FBA, so that management different from DB should be regarded with the aim of decreasing negative bronchoscopy rates. We have no defined the best diagnostic-therapeutic

approach for them as it is out of the scope of this work, but CT or clinical surveillience could be acceptable.

This study have some limitations, mainly its retrospective nature. The positive bronchoscopy rate is poor, so conclusions should be prudently consider. A prospective model's validation is necessary to obtain its real diagnostic accuracy which we are working on.

In conclusion, it is possible to estimate the risk of FBA based on clinical charts (dyspnea/tachypnea), physical findings (asymmetric auscultation) and radiological tests (altered chest X-ray). The type of foreign body has a predictive value for the presence of a foreign body and could guide clinical management. According to this study, the risk of FBA is higher than 50 % when the material suspected are peanuts or seeds, so DB is justified as the first diagnostic test. For other foreign bodies (organic, inorganic or not specified), whose risk is significantly lower, the predictive model proposed can be useful to identify patients at low pre-test probability of FBA to whom approach different from bronchoscopy should be considered.

Finnancial support statement

This research did not receive any specific grant from funding agencies in the public, commercial, or not-for-profit sectors.

Ethic recommendations

This paper respect privacy rights of human subjects and ethics recommendations in publishing.

Declaration of generative AI in scientific writing

Authors declare that no Generative AI or AI-assisted technologies have been used in the writing process.

CRediT authorship contribution statement

Maria Martinez Diaz: Writing – original draft, Resources, Project administration, Investigation, Data curation, Conceptualization. **Vicente Ibañez Pradas:** Supervision, Methodology, Formal analysis. **Miguel Couselo Jerez:** Writing – review & editing, Supervision. **Estíbaliz Valdés Diéguez:** Supervision.

Declaration of competing interest

Authors have no conflicts of interest to disclose.

References

[1] M.A. Moslehi, Failures in emergency management of pediatric airway foreign bodies by rigid bronchoscopy: we have yet to complete our learning, World J. Pediatr. Surg. 7 (5) (2022) e000321, https://doi.org/10.1136/wjps-2021.
[2] J.R. Sink, D.J. Kitsko, M.W. Georg, et al., Predictors of Foreign Body Aspiration in Children, Otolaryngol. Head Neck Surg. 155 (2016) 501–507, https://doi.org/10.1177/0194599816644410.
[3] J.L. Antón-Pacheco, R. Martín-Alelú, M. López, et al., Foreign body aspiration in children: treatment timing and related complications, Int. J. Pediatr. Otorhinolaryngol. 144 (2021) 110690, https://doi.org/10.1016/j.ijporl.2021.110690.
[4] C. Sheehan, J. Lopez, C. Elmaraghy, Low rate of positive bronchoscopy for suspected foreign body aspiration in infants, Int J Pediatr. Otorhinolaryngol. 104 (2018) 72–75, https://doi.org/10.1016/j.ijporl.2017.10.030.
[5] N.A. Fasseeh, O.A. Elagamy, A.H. Gaafar, et al., A new scoring system and clinical algorithm for the management of suspected foreign body aspiration in children: a retrospective cohort study, Ital. J. Pediatr. 47 (2021) 194, https://doi.org/10.1186/s13052-021-01147-9.
[6] J. Lluna, M. Olabarri, A. Domènech, et al., Recomendaciones sobre la prevención de aspiraciones de cuerpos extraños, An. Pediatr. 86 (2017) 50.e1–50.e6.
[7] A. Lobeiras Tuñon, Ingesta-aspiración de cuerpo extraño, Protocolo diagnostico terapéutico pediatría 1 (2020) 339–355.
[8] M. Lee, D.J. Kim, H.B. Jang, et al., Risk factors affecting the treatment outcome of pediatric foreign body aspiration: significance of time factors, Pediatric. Surg. Int 36 (2020) 1061–1066, https://doi.org/10.1007/s00383-020-04714-z.
[9] G.X. Tan, E.F. Boss, D.S. Rhee, Bronchoscopy for pediatric airway foreign body: thirty-day adverse outcomes in the ACS NSQIP-P, Otolaryngol. Head. Neck. Surg. 160 (2019) 326–331, https://doi.org/10.1177/0194599818800470.
[10] O. Cavel, M. Bergeron, L. Garel, et al., Questioning the legitimacy of rigid bronchoscopy as a tool for establishing the diagnosis of a bronchial foreign body, Int. J. Pediatr. Otorhinolaryngol. 76 (2012) 194–201, https://doi.org/10.1016/j.ijporl.2011.11.002.
[11] Stephen G. Pauker, Jerome P. Kassirer, The Threshold Approach to Clinical Decision Making, N. Engl. J. Med. 302 (1980) 1109–1117, https://doi.org/10.1056/NEJM198005153022003.
[12] B. Djulbegovic, J. van den Ende, R.M. Hamm, et al., When is rational to order a diagnostic test, or prescribe treatment: the threshold model as an explanation of practice variation, Eur. J. Clin. Invest. 45 (2015) 485–493, https://doi.org/10.1111/eci.12421.
[13] S.G. Pauker, J.P. Kassirer, Therapeutic decision making: a cost-benefit analysis, N. Engl J. Med. 293 (1975) 229–234, https://doi.org/10.1056/NEJM197507312930505.
[14] T.J. Sumanth, B.D. Bokare, D.M. Mahore, et al., Management of tracheobronchial foreign bodies: a retrospective and prospective study, Ind. J. Otolaryngol. Head Neck Surg. 66 (2014) 60–64, https://doi.org/10.1007/s12070-011-0302-y.
[15] A.T. Gibbons, A.M. Casar Berazaluce, R.E. Hanke, et al., Avoiding unnecessary bronchoscopy in children with suspected foreign body aspiration using computed tomography, J. Pediatr. Surg. 55 (2020) 176–181, https://doi.org/10.1016/j.jpedsurg.2019.09.045.
[16] V. Pitiot, M. Grall, D. Ploin, et al., The use of CT-scan in foreign body aspiration in children: a 6 years' experience, Int. J. Pediatr. Otorhinolaryngol. 102 (2017) 169–173, https://doi.org/10.1016/j.ijporl.2017.08.036.
[17] S. Na'ara, I. Vainer, M. Amit, et al., Foreign body aspiration in infants and older children: a comparative study, Ear Nose Throat J. 99 (2020) 47–51, https://doi.org/10.1177/0145561319839900.
[18] L. Even, N. Heno, Y. Talmon, et al., Diagnostic evaluation of foreign body aspiration in children: a prospective study, J. Pediatr. Surg. 40 (2005) 1122–1127, https://doi.org/10.1016/j.jpedsurg.2005.03.049.
[19] J.J.W. Lee, J. Philteos, M. Levin, et al., Clinical prediction models for suspected pediatric foreign body aspiration: a systematic review and meta-analysis, JAMA Otolaryngol. Head Neck Surg. 147 (2021) 787–796, https://doi.org/10.1001/jamaoto.2021.1548.
[20] M. Valdivieso Castro, I. Tuduri Limousin, T.M. Cardenal Alonso-Allende, et al., Protocolo probabilístico para el manejo del cuerpo extraño en la vía aérea, Cir. Pediatr. 31 (2018) 162–165. PMID: 30371026.
[21] I. Miró, V. Ibáñez, E. Carazo, et al., Aplicabilidad de un score clínico en pacientes con sospecha de aspiración de cuerpo extraño, Cir. Pediatr. 32 (2019) 172–176.
[22] G. Özyüksel, U.E. Arslan, Ö. Boybeyi-Türer, et al., New scoring system to predict foreign body aspiration in children, J. Pediatr. Surg. 55 (2020) 1663–1666, https://doi.org/10.1016/j.jpedsurg.2019.12.015.
[23] I.A. Janahi, S. Khan, P. Chandra, et al., A new clinical algorithm scoring for management of suspected foreign body aspiration in children, BMC Pulm. Med. 17 (2017) 61, https://doi.org/10.1186/s12890-017-0406-6.
[24] P. Stafler, Y. Nachalon, Y. Stern, et al., Validation of a computerized scoring system for foreign body aspiration: an observational study, Pediatr. Pulmonol. 55 (2020) 690–696, https://doi.org/10.1002/ppul.24632.
[25] G. Kadmon, Y. Stern, E. Bron-Harlev, et al., Computerized scoring system for the diagnosis of foreign body aspiration in children, Ann. Otol. Rhinol. Laryngol. 117 (2008) 839–843, https://doi.org/10.1177/000348940811701108.
[26] G. Ünal, A.İ. Yılmaz, T. Tok, et al., Use of flexible bronchoscopy in foreign body aspiration, Turk. Arch. Otorhinolaryngol. 60 (2022) 88–94, https://doi.org/10.4274/tao.2022.2022-6-6.
[27] C.W. Fidkowski, H. Zheng, P.G. Firth, The anesthetic considerations of tracheobronchial foreign bodies in children: a literature review of 12,979 cases, Anesth. Analg. 111 (2010) 1016–1025, https://doi.org/10.1213/ANE.0b013e3181ef3e9c.
[28] O.G. Ahmed, R.P. Guillerman, C.M Giannoni, Protocol incorporating airway CT decreases negative bronchoscopy rates for suspected foreign bodies in pediatric patients, Int. J. Pediatr. Otorhinolaryngol. 109 (2018) 133–137, https://doi.org/10.1016/j.ijporl.2018.03.016.